

## Adenoid Basal Carcinoma of the Uterine Cervix - A Case Report -

Youn Kyung Lee • Ho Jong Jeon  
and Keun Hong Kee

Department of Pathology, Chosun  
University Medical College, Kwangju,  
Korea

Received : December 7, 2000  
Accepted : May 7, 2001

**Corresponding Author**

Keun-Hong Kee, M.D.  
Department of Pathology, Chosun University Hospital,  
588 Seosuk-dong, Dong-ku, Kwangju 501-140, Korea  
Tel: 062-220-3276  
Fax: 062-234-4584  
E-mail: khkee@mail.chosun.ac.kr

We report a case of adenoid basal carcinoma of the uterine cervix unexpectedly found in a 68-year-old female. She was diagnosed with a high-grade squamous intraepithelial lesion (HSIL) on a cervical smear and subsequent cervical punch biopsy. Total abdominal hysterectomy was performed, and there were no significant gross findings in the uterine cervix. Microscopically, the epithelial surface showed a HSIL with glandular extension. Below the neoplastic epithelial lesion were numerous small nests of uniform small cells, which extended to the parametrium. These tumor cells contained hyperchromatic nuclei, inconspicuous nucleoli, and scant cytoplasm. Peripheral palisading and gland-like or acinar structures in the nests were noted. The latter were positive for mucicarmine stain. Foci of squamous differentiation exhibiting occasional mitoses and large atypical cells were seen in the small nests. Stromal reaction was not obvious. Immunohistochemically, the HSIL lesion and adenoid basal carcinoma lesion were negative for human papilloma virus. The tumor cells forming nests were positive for carcinoembryonic antigen, S-100 protein, and high molecular weight cytokeratin, but were negative for  $\alpha$ -smooth muscle actin and chromogranin A.

**Key Words** : Adenoid basal carcinoma, Cervix uteri

Adenoid basal carcinoma of the uterine cervix is uncommon.<sup>1-7</sup> It is thought to be derived from the multipotential basal or reserve cell layer of the cervical epithelium,<sup>2,3</sup> but the histogenesis has not been confirmed. It is characterized by nests and cords of small uniform cells with peripheral palisading resembling that of basal cell and basosquamous cell carcinoma of the skin. Adenoid basal carcinoma is usually associated with cervical intraepithelial neoplasia (CIN) or carcinoma *in situ* (CIS). The prognosis of this tumor is usually favorable, distinguishing it from the more aggressive adenoid cystic carcinoma of the uterine cervix.<sup>2</sup> We report a case of adenoid basal carcinoma of the uterine cervix in a 68-year-old female, whose uterus was resected to treat a high-grade squamous intraepithelial lesion (HSIL).

### CASE REPORT

The patient was a 68-year-old woman (gravida 6, para 5) who underwent menopause at age 50. Twenty years earlier, she had undergone a laminectomy due to herniation of the

nucleus pulposus of L4-5. The rest of her history, as well as her family history were non-contributory. The patient visited a local clinic for abnormal genital bleeding. Several degenerative cells with atypia were seen on her cervicovaginal smear, and she was referred to our hospital for definite diagnosis and treatment. On colposcopic evaluation, a 3 × 5 cm erosion was seen on the uterine cervix, and gentle touch caused bleeding. On the cervicovaginal smear, atypical squamous cells of HSIL were found. On physical examination, the uterus was atrophic and both ovaries and salpinges appeared normal with no palpable mass or tenderness. Total abdominal hysterectomy with bilateral salphingo-oophorectomy was performed.

Grossly, no recognizable mass was seen in the cervix of the resected uterus. Microscopically, the surface epithelium of the uterine cervix contained squamous cell carcinoma *in situ* lesions with glandular extension. Small, round-to-oval neoplastic cell nests were observed in the stroma deep beneath the CIS lesion. These nests were composed of small, uniform cells with hyperchromatic nuclei, inconspicuous nucleoli, and scant cytoplasm. Peripheral palisading (Fig.

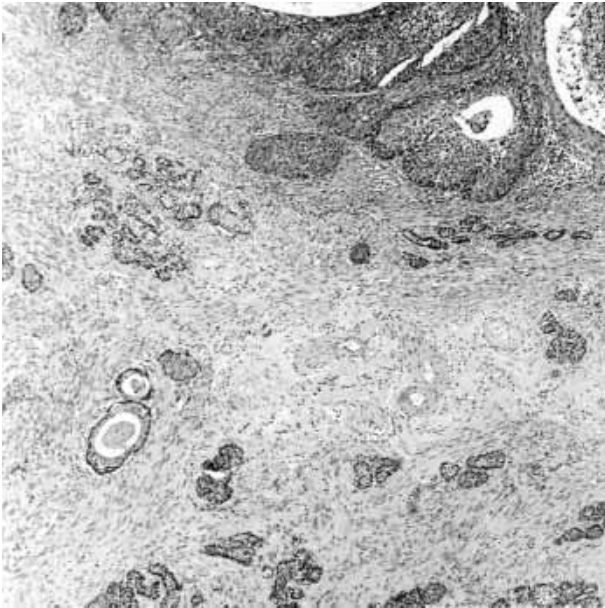


Fig. 1. Microscopically, the surface epithelium of the uterine cervix shows carcinoma *in situ* lesions with glandular extension. Small round-to-oval neoplastic cell nests are observed in the stroma deep beneath the carcinoma *in situ*.

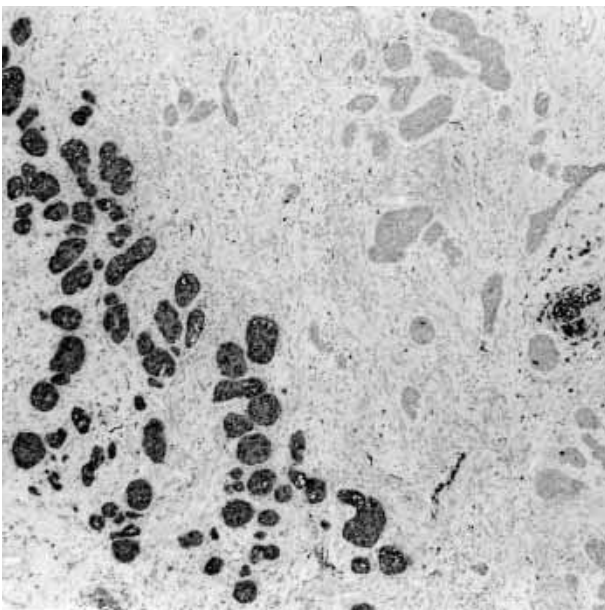


Fig. 3. Immunohistochemically, the tumor cells were partly positive for S-100 protein.

2A) and gland-like or acinar structures (Fig. 2B) were also noted in some areas. These areas stained positively for mucicarmine and PAS. Mitotic activity was low, stromal reaction was not obvious, and necrosis was not observed. There were also foci of squamous differentiation in portions of the small

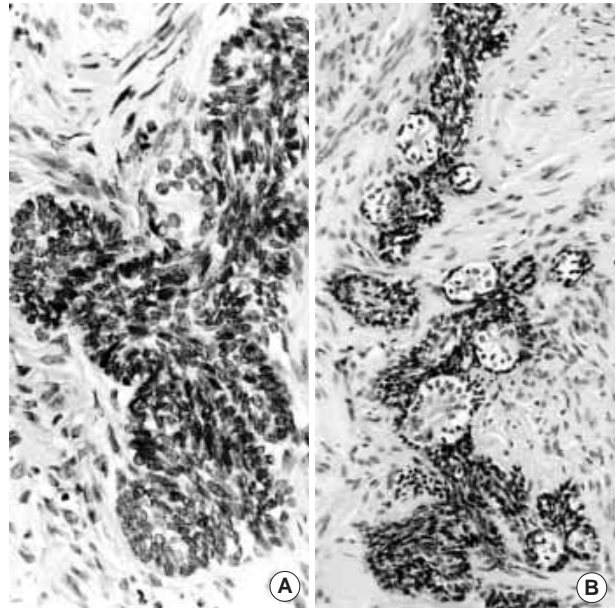


Fig. 2. Tumor nests are composed of small, uniform cells with hyperchromatic nuclei, inconspicuous nucleoli, and scant cytoplasm. Peripheral palisading is observed (A). Gland-like or acinar structures were also noted in some areas (B).

nests. The lesions extended to the parametrium and to the lower portion of the myometrium. Immunohistochemically, the CIS lesion and adenoid basal carcinoma were negative for human papilloma virus (HPV). The adenoid basal carcinoma cells were positive for high molecular weight cytokeratin, S-100 protein (Fig. 3) and carcinoembryonic antigen, and they were negative for chromogranin A and  $\alpha$ -smooth muscle actin. Both ovaries were atrophic, and there was no evidence of metastatic disease.

## DISCUSSION

Adenoid basal carcinoma is an uncommon cervical malignancy. There have been about 35 cases reported in the world to date. Baggish and Woodruff<sup>1</sup> first recognized adenoid basal carcinoma of the cervix as a distinct type of cervical neoplasm in 1966. They reported three unusual cervical tumors which were characterized by nested proliferation of uniform basal-type cells with peripheral palisade arrangement punctuated by small acini located deep within the cervical stroma. Each tumor was associated with squamous cell carcinoma *in situ*. The coexistence of adenoid basal carcinoma with dysplasia or carcinoma *in situ* also has been reported. Its existence is rarely detected by cervical smear

because it is usually located beneath the epithelium, although there have been a few reports of adenoid basal carcinoma detected by cervicovaginal smear.<sup>5,6</sup> Powers *et al.*<sup>5</sup> reported that the smear finding is characterized by a few aggregates of small, uniform cells with hyperchromatic nuclei or syncytial fragments of small basaloid cells showing a high nuclear/cytoplasmic ratio with an irregular nuclear membrane and stippled chromatin. In the present case, a HSIL with no connection to the adenoid basal carcinoma lesion was observed.

Most adenoid basal carcinomas occur in postmenopausal women. They are slow-growing tumors that do not metastasize. Grossly, in most cases the cervix appears normal and there is no palpable mass, and therefore it is rarely recognized by clinicians or pathologists. Nevertheless, the patient's prognosis is favorable. The tumor does not contain estrogen or progesterone receptors.<sup>3</sup> Radical surgery is the treatment of choice. In our case, the diagnosis was missed because there was no visible lesion and no detectable mass in the uterine cervix of this postmenopausal woman.

In most reported cases, this tumor is associated with cervical intraepithelial neoplasia. Our case was associated with a high-grade squamous intraepithelial lesion. It is difficult to speculate whether the associated CIN lesions play any role in the pathogenesis of adenoid basal carcinoma because of the limited number of cases that have been studied. HPV appears to be involved in the mechanism of tumor development since the HPV genome, especially that of high-risk types, is found in 67% of adenoid basal carcinomas.<sup>2,7</sup> Our case was HPV negative. Further studies on adenoid basal carcinoma should also focus on the association with HPV.

Some studies have examined the histogenesis of adenoid basal carcinoma using immunohistochemical staining or molecular biology methods. The tumor cells expressed carcinoembryonic antigen (CEA) and keratin 7, 8, 14, 17, 18, and 19, but were negative for S-100 protein and actin. These findings suggest that the tumor cells originated from the multipotential basal or reserve cell layer of the cervical epithelium. Some cases have been positive for S-100 protein, indicative of myoepithelial differentiation.<sup>3</sup> The histogenesis of these tumors has not been confirmed. In our case, CEA was strongly positive, while some tumor cells were S-100 protein positive.

Adenoid basal carcinoma should be identified and distin-

guished clinically and pathologically from other cervical malignant lesions including the solid variant of adenoid cystic carcinoma, squamous cell carcinoma with basaloid features, endocervical adenocarcinoma, and small cell carcinoma. Adenoid cystic carcinoma has a poorer prognosis. The solid variant of adenoid cystic carcinoma consists of small, undifferentiated, or basaloid cells with areas of necrosis and increased mitotic figures and has abundant PAS-positive basement membrane material, while adenoid basal carcinoma contains some gland-like structures with rare mitoses and necrosis. Squamous cell carcinoma with basaloid features consists of clearly malignant cells with no gland formation. Endocervical adenocarcinoma has obvious atypical glands and lacks peripheral palisading. In carcinoid tumors and small cell carcinomas, neurosecretory granules and diffuse immunoreactivity for neuroendocrine markers (e.g., chromogranin A) are characteristic.

## REFERENCES

1. Baggish MS, Woodruff JD. Adenoid basal carcinoma of the cervix. *Obstet Gynecol* 1966; 28: 213-8.
2. Grayson W, Taylor LF, Cooper K. Adenoid cystic and adenoid basal carcinoma of the uterine cervix: comparative morphologic, mucin, and immunohistochemical profile of two rare neoplasms of putative 'reserve cell' origin. *Am J Surg Pathol* 1999; 23: 448-58.
3. Senzaki H, Osaki T, Uemura Y, *et al.* Adenoid basal carcinoma of the uterine cervix: immunohistochemical study and literature review. *Jpn J Clin Oncol* 1997; 27: 437-41.
4. Ferry JA, Scully RE. "Adenoid cystic" carcinoma and adenoid basal carcinoma of the uterine cervix. A study of 28 cases. *Am J Surg Pathol* 1988; 12: 134-44.
5. Powers CN, Stastny JF, Frable WJ. Adenoid basal carcinoma of the cervix: a potential pitfall in cervicovaginal cytology. *Diagn Cytopathol* 1996; 14: 172-7.
6. Langlois NE, Miller ID, Mann EM. Adenoid basal carcinoma of the cervix: an unusual cytological appearance. *Cytopathology* 1995; 6: 104-9.
7. Kim HJ, Kim DW, Jin SY, Lee DW. Adenoid basal carcinoma associated with invasive squamous cell carcinoma of uterine cervix. *Korean J Pathol* 1996; 30: 739-41.