

## Primary Choriocarcinoma of the Stomach - A Case Report -

Eun Joo Seo, Hi Jeong Kwon  
Ki Ouk Min, Keun Woo Lim<sup>1</sup>  
Seong Lee<sup>1</sup> and Byung Kee Kim

Departments of Clinical Pathology and  
<sup>1</sup>General Surgery, College of Medicine,  
the Catholic University of Korea, Seoul,  
Korea

Received : May 12, 2001  
Accepted : October 12, 2001

### Corresponding Author

Hi Jeong Kwon, M.D.  
Department of Clinical Pathology, St. Paul's Hospital,  
620-56, Jeonnong-dong, Dongdaemoon-gu, Seoul  
130-709, Korea  
Tel: 02-958-2395  
Fax: 02-957-8836  
E-mail: hjkkwon@unitel.co.kr

\*This paper was supported by the grant from the St.  
Paul's Hospital Research Fund.

A case of primary gastric choriocarcinoma with multiple liver metastases is described. A 54-year-old man underwent gastrectomy for an advanced cancer. An ulcerofungating tumor with extensive hemorrhagic necrosis was found in the anterior wall of the prepyloric antrum. The histologic examination revealed a biphasic pattern composed of uninucleated cyto or intermediate trophoblasts and syncytiotrophoblasts. A small area of the adenocarcinoma forming glandular structures and poorly differentiated solid sheets was also noted on the superficial portion of the tumor. Immunohistochemical staining for the beta human chorionic gonadotropin ( $\beta$ -hCG) and the human placental lactogen (hPL) showed strong immunoreactivity, particularly in the cytoplasm of the syncytiotrophoblasts and intermediate trophoblasts, respectively. A diagnosis of the choriocarcinoma was made. Multiple hepatic nodules consistent with metastases were noted on the abdominal sonogram. The serum  $\beta$ -hCG level of the patient was significantly increased.

**Key Words :** Stomach Neoplasms

The majority of choriocarcinomas occur in the uterus as gestational malignant tumors. Nongestational choriocarcinoma also arises infrequently in the gonads or extragonadal midline sites including the mediastinum, retroperitoneum, and near or in the pineal gland, where the tumors are speculated to originate from displaced germ cells during embryonal development.<sup>1</sup> Rarely, choriocarcinoma appears in other parenchymal organs such as the gastrointestinal tract; and in this case, the tumor is assumed to arise from a different histogenetic origin compared with the tumors of extragonadal sites.<sup>2,3</sup> The choriocarcinoma of the gastrointestinal tract commonly accompanies adenocarcinoma and may contain a transitional component between the adenocarcinoma and choriocarcinoma. For the histogenetic theory of the gastrointestinal choriocarcinoma, retrodifferentiation of neoplastic epithelial cells can be adopted.<sup>1-3</sup> Although the stomach is the most common site in the gastrointestinal tract,<sup>4</sup>

the primary gastric choriocarcinoma is still a rare aggressive malignant tumor.

### CASE REPORT

A 54-year-old man with severe dizziness was admitted to the otolaryngology department of our Hospital. He had suffered from intermittent tarry stool for 1 month prior to admission. He had a medical history of hepatitis 18 years prior to this visit, which was declared to be completely recovered clinically after two years of treatment and follow-up. He had been smoking one pack a day for 30 years. There was no gynecomastia. On gastric fiberoptic examination, a large ulcerofungating mass in the anterior wall of the prepyloric antrum was noted (Fig. 1). Multiple hepatic metastases were also confirmed by abdominal

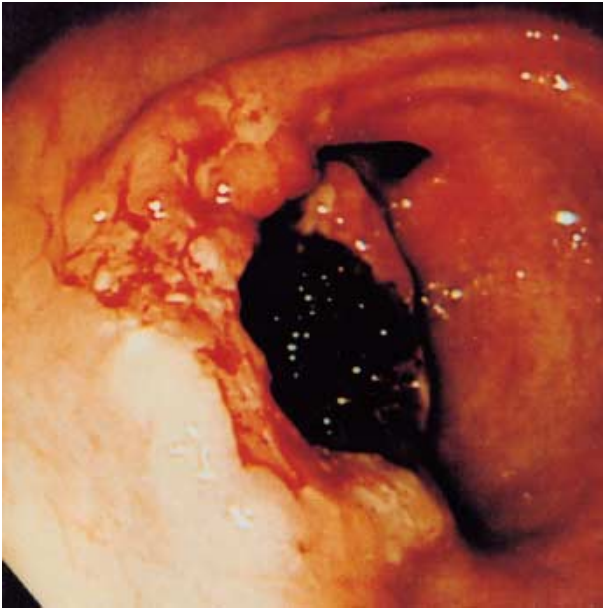


Fig. 1. Gastric fiberoscopic examination reveals an ulcerofungating mass with hemorrhage in the prepyloric antrum.

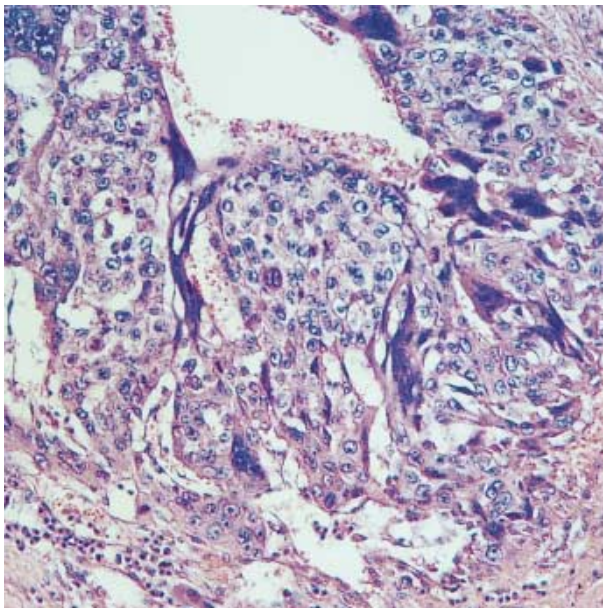


Fig. 2. Microscopic findings of choriocarcinoma shows dimorphic mixture of mononucleated cytotrophoblasts and directly apposed syncytiotrophoblasts with multiple nuclei and deeply eosinophilic cytoplasm.

sonogram, but no other sites including the gonads displayed any tumor masses. A subtotal gastrectomy was performed. A large friable, ulcerofungating mass measuring 4×4 cm, with extensive hemorrhage and necrosis, almost obstructing the lumen, was discovered in the anterior wall of the prepyloric

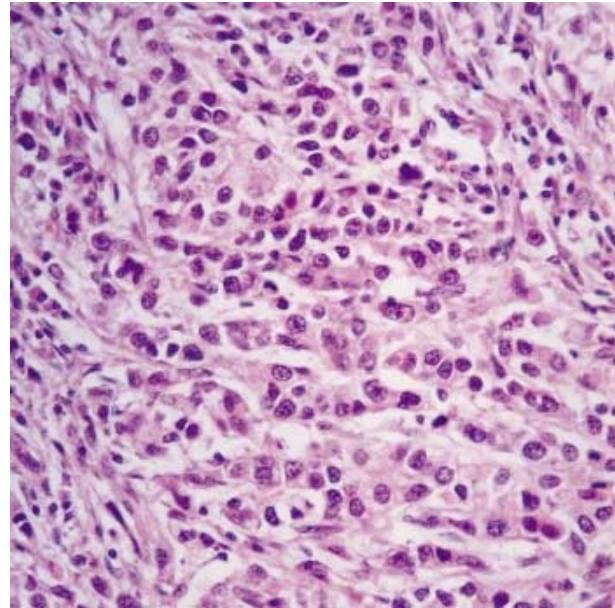


Fig. 3. Adenocarcinomatous area is composed of tubules and solid growth of tumor cells.

Table 1. Immunohistochemical reactivities of normal gastric gland, adenocarcinomatous and choriocarcinomatous area

	Normal gland	Adenocarcinoma	Choriocarcinoma
hCG	-	-	++
hPL	-	-	+
EMA	++	+	+
CK	++	+	+
CEA	-	++	-
VM	-	-	-

hCG:  $\beta$ -human chorionic gonadotropin, hPL: human placental lactogen, EMA: epithelial membrane antigen, CK: cytokeratin, CEA: carcinoembryonic antigen, VM: vimentin.

antrum. The cut surfaces of the tumor exhibited invasion of the serosal surface. Microscopic findings mainly exhibited a choriocarcinomatous component (over 95% of tumor mass) with biphasic cellular patterns of cytotrophoblasts and syncytiotrophoblasts (Fig. 2). The choriocarcinomatous component had invaded the serosa. A small area of a glandular or solid adenocarcinomatous component was observed on a superficial portion of the tumor (Fig. 3). The transitional area between the choriocarcinoma and adenocarcinoma was not clearly detected. Multiple vascular tumor emboli were observed. Metastatic sites of the lymph nodes displayed both choriocarcinoma and adenocarcinoma components. The immunohistochemical stains for beta human chorionic gonadotropin ( $\beta$ -hCG, 1:50, Zymed, San Francisco, U.S.A.), human placental lactogen (hPL, 1:100, Neo Markers, Fremont, CA, U.S.A.), carcinoembryonic antigen

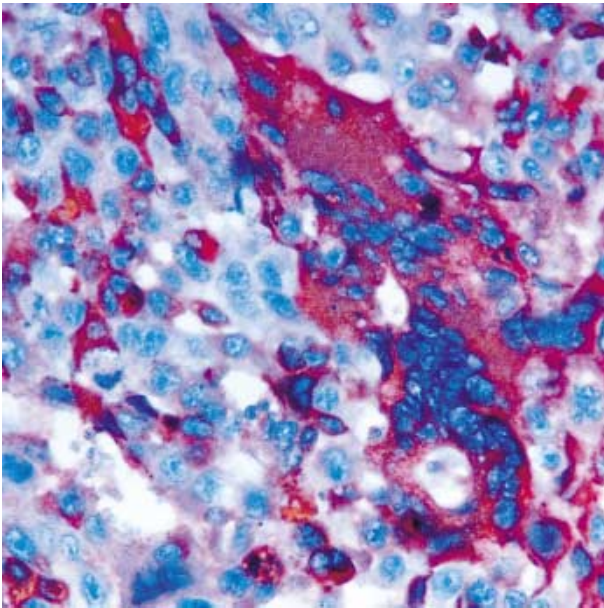


Fig. 4. Immunostain for  $\beta$ -human chorionic gonadotropin shows strong positive reaction mainly in the cytoplasm of multinucleated syncytiotrophoblasts.

(1:300, Dako, Carpinteria, CA, U.S.A.), vimentin (1:300, Dako, Carpinteria, CA, U.S.A.), epithelial membrane antigen (1:100, Dako, Carpinteria, CA, U.S.A.) and cytokeratin (1:50, Dako, Carpinteria, CA, U.S.A.) were performed (Table 1). The  $\beta$ -hCG had localized intensely in the syncytiotrophoblastic cells (Fig. 4) whereas the hPL was stained in the intermediate trophoblasts (Fig. 5). The p53 protein (1:100, Dako, Carpinteria, CA, U.S.A.) immunoreactivity was found in 67% of choriocarcinomatous area and 45% of adenocarcinomatous area. The high MIB-1 (1:100, Dako, Carpinteria, CA, U.S.A.) labelling index was equally analyzed in both the choriocarcinomatous and adenocarcinomatous area. The carcinoembryonic antigen level (0.66 ng/mL) was within normal range.

A retrograde examination of serum  $\beta$ -hCG using the serum sample which had been stored one day prior to the gastrectomy revealed 6,487 IU/L. The patient was treated with EMA chemotherapy regimen comprising of VP16 (100 mg/m<sup>2</sup>, intravenous, day 1), methotrexate (100 mg/m<sup>2</sup>, intravenous, day 1), and dactinomycin (0.5 mg, intravenous, day 1). This chemotherapy was repeated every week. The follow-up levels of serum  $\beta$ -hCG were continuously and markedly increased up to 24,601 IU/L, and reduced to the level of 2,711 IU/L after 3 courses of chemotherapy. In accordance to the emergence of bone and lung metastases during late follow-up, the serum  $\beta$ -hCG was increased again (13,834 IU/L), and the patient died. In contrast to  $\beta$ -hCG, the serum level of hPL was not increased.

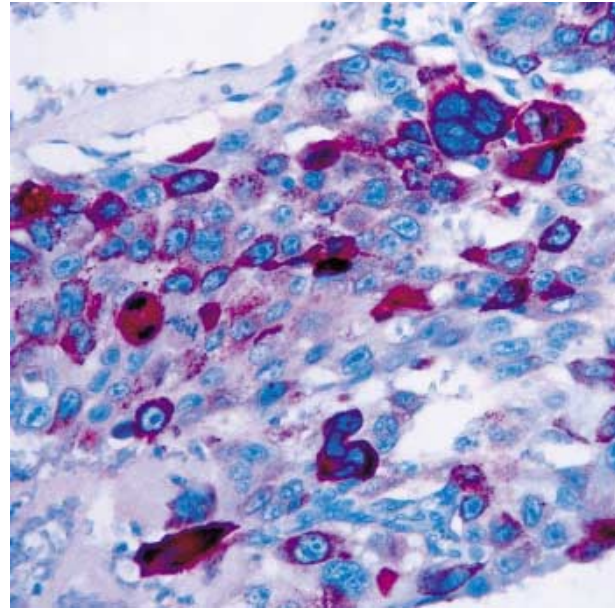


Fig. 5. Immunostain for human placental lactogen. The positivity is noted in the cytoplasm of intermediate trophoblasts with single nucleus or multiple nuclei.

## DISCUSSION

The primary gastrointestinal choriocarcinoma is a rare malignant tumor with rapid metastasis to the liver and lung. The stomach is the most frequent site in the gastrointestinal tract.<sup>4</sup>

More than 120 cases of primary choriocarcinomas have been reported, and about 80 of these cases are documented in Japanese.<sup>3</sup> In domestic literature, only 5 cases of primary gastric choriocarcinomas, including 2 cases associated with hepatoid carcinoma<sup>5</sup> and endodermal sinus tumor,<sup>6</sup> in addition to adenocarcinoma component, have been reported. The choriocarcinoma is characterized by biphasic histologic patterns composed of cytotrophoblasts and syncytiotrophoblasts, and a positive cytoplasmic hCG reaction of tumor cells on immunohistochemical stains, as well as an increased serum hCG level in the blood.<sup>7</sup> The hCG can also be detected in the patient's serum or tissue section of usual adenocarcinoma of the stomach,<sup>8</sup> and in this regard, the constellation of histologic, immunohistochemical and serologic findings are important for the final diagnosis of the choriocarcinoma. The present case showed a typical biphasic histologic pattern with positive  $\beta$ -hCG and hPL cytoplasmic reactions of trophoblasts on immunohistochemical stains. A high  $\beta$ -hCG level was also detected in the serum of the patient.

Diverse theories to explain the development of the gastrointestinal choriocarcinoma were proposed.<sup>1-3</sup> Hypotheses for the development of gastric choriocarcinoma in the displaced

gonadal anlage, the development from gastric teratoma, the long delayed metastasis from uterine or gonadal primary choriocarcinoma, or retrodifferentiation or opisthoplegia of the pre-existing adenocarcinoma can be listed. Among these, the explanation of the metaplasia or retrodifferentiation of adenocarcinoma cells to trophoblasts is most widely accepted.<sup>1-3</sup> Support for this theory comes from the frequent occurrence of a choriocarcinomatous component in the adenocarcinoma of the stomach, similar age and sex distribution of those who have gastric choriocarcinoma to adenocarcinoma, and the highest incidence rate in Japan, where adenocarcinomas occur most frequently.<sup>1</sup> The clinicopathological findings of our case also provide evidence for the retrodifferentiation or dedifferentiation theory. The patient presented in this case was a man and 54 years old. The pathologic findings showed a small portion of the adenocarcinoma in addition to the main and bulky area of the choriocarcinoma, although no clear transition zone was noted between the two components. The metastatic lymph nodes revealed both choriocarcinoma and adenocarcinoma components.

The adenocarcinoma combined with a choriocarcinomatous area along with increased serum hCG is known to have a very aggressive biological behavior and a poorer outcome, when compared to pure adenocarcinomas.<sup>3,9</sup> The chemotherapeutic regimens are also different from ordinary adenocarcinoma of the stomach. Therefore, in the case of a poorly differentiated adenocarcinoma of the stomach or other sites, meticulous examination for the detection of trophoblastic differentiation on the tissue section, and evaluation of serum hCG should be made.

## REFERENCES

1. Wurzel J, Brooks JJ. Primary gastric choriocarcinoma: immunohistochemistry, postmortem documentation, and hormonal effects in a postmenopausal female. *Cancer* 1981; 48: 2756-61.
2. Garcia RL, Ghali VS. Gastric choriocarcinoma and yolk sac tumor in a man: observations about its possible origin. *Hum Pathol* 1985; 16: 955-8.
3. Imai I, Kawabe T, Takahashi M, et al. A case of primary gastric choriocarcinoma and a review of the Japanese literature. *J Gastroenterol* 1994; 29: 642-6.
4. Ordonez NG, Luna MA. Choriocarcinoma of the colon. *Am J Gastroenterol* 1984; 79: 39-42.
5. Jung KC, Kim WH, Kim YI, Choe KJ. Gastric adenocarcinoma with choriocarcinomatous and hepatoid differentiation: report of a case. *Korean J Pathol* 1994; 28: 409-13.
6. Kim EK, Hong EK, Lee KS, Lee JD. Gastric choriocarcinoma and endodermal sinus tumor in collision tumor. *Korean J Pathol* 1992; 26: 405-10.
7. Silverberg SG, Kurman RJ. Choriocarcinoma. In: Silverberg SG, Kurman RJ, eds. *Tumors of the uterine corpus and gestational trophoblastic disease*. Washington, D.C.: Armed Forces Institute of Pathology, 1992; 252-63.
8. Yakeishi Y, Mori M, Enjoji M. Distribution of  $\beta$ -human chorionic gonadotropin-positive cells in noncancerous gastric mucosa and in malignant gastric tumors. *Cancer* 1990; 66: 695-701.
9. Ito H, Tahara E. Human chorionic gonadotropin in human gastric carcinoma. A retrospective immunohistochemical study. *Acta Pathol Jpn* 1983; 33: 287-96.