

Mesothelial Cell Inclusions Mimicking Metastatic Carcinoma in Mediastinal Lymph Node – A Case Report –

Young Min Kim • Kyu-Rae Kim
Jae Y. Ro

Department of Pathology, University of
Ulsan College of Medicine, Asan
Medical Center, Seoul, Korea

Received : September 2, 2003
Accepted : November 20, 2003

Corresponding Author

Jae Y. Ro, M.D.
Department of Pathology, University of Ulsan College
of Medicine, Asan Medical Center, 388-1
Pungnap-dong, Songpa-gu, Seoul 138-736, Korea
Tel: 02-3010-4560
Fax: 02-472-7898
E-mail: jaero@amc.seoul.kr

The presence of benign mesothelial cell inclusions in the mediastinal lymph node is extremely rare and thus difficult for the pathologist distinguishing from sinus histiocytosis, metastatic carcinoma, or metastatic mesothelioma. We recently had a case of benign mesothelial cell inclusions in the mediastinal lymph node, which is initially misinterpreted as metastatic carcinoma of unknown origin. However, further clinical studies failed to identify the primary site. Subsequent immunostaining with calretinin demonstrated the strong nuclear and cytoplasmic immunoreactivity, suggesting that these cells are mesothelial cells. It is important that when the nodal changes resemble metastatic carcinoma morphologically in the mediastinal lymph nodes, but the primary site can not be identified clinically, the possibility of mesothelial cell inclusions should be raised and the proper use of immunohistochemistry in conjunction with a clinical finding is recommended.

Key Words : Inclusion-Mediastinum-Mesothelium

Mesothelial cell inclusions in lymph nodes are extremely rare and have been reported in the sinuses of mediastinal and abdominal lymph nodes. These mesothelial cell inclusions are occasionally mistaken as sinus histiocytosis or metastatic carcinoma.¹⁻⁶ We recently experienced a case of benign mesothelial cell inclusions in the mediastinal lymph node, which is initially misinterpreted as metastatic carcinoma of unknown origin. We report a case of benign mesothelial cell inclusions and review the literature.

CASE REPORT

A 65-year-old male patient was initially referred to our hospital with the diagnosis of abdominal aortic aneurysm from a local clinic. Preoperative examinations revealed the triple vessel diseases of coronary arteries and mediastinal (subcarinal, A-P window, and left lower paratracheal) lymphadenopathies, measuring up to 1.0 cm in dimension (Fig. 1). Therefore, coronary artery bypass graft was performed along with the

intraoperative lymph node biopsy to exclude the possibility of lymphoma, tuberculosis, or metastasis. Grossly, the submitted subcarinal node measured 1.0 × 0.5 × 0.5 cm. The cut surface was yellowish tan, smooth to mottled, and grossly no abnormal lesion was identified.

Microscopically, round to polygonal epithelioid cells were detected singly or in small clusters in the subcapsular and interfollicular sinuses of the mediastinal lymph node (Fig. 2). The cells had the central vesicular nucleus with abundant eosinophilic cytoplasmic granules. The mitotic activity was not detected. In addition, glandular or papillary formations, stromal reaction, or distortion of the nodal architecture was not detected. We initially performed immunohistochemical stainings using various antibodies to verify the nature of the epithelioid cells. These cells were strongly positive for cytokeratin (AE1/AE3) (1:50, Zymed, San Francisco, USA)(Fig. 3A), but negative for CD68 (1:8,000, Dako, Denmark), leukocyte common antigen (1:200, Dako, Denmark), cytokeratin 7 and 20 (1:200, Dako, Denmark), thyroid transcription factor-1 (1:200, Novocastra, UK) and prostate specific antigen

(1:200, Dako, Denmark). Based on the initial immunohistochemical results, these epithelioid cells were misinterpreted as metastatic carcinoma of unknown origin. However, subsequent clinical examinations failed to identify the primary site. Because of the clinical and pathological discrepancy, the possibility of their mesothelial nature was raised and subsequently immunostaining with calretinin (1:50, Zymed, San Francisco,

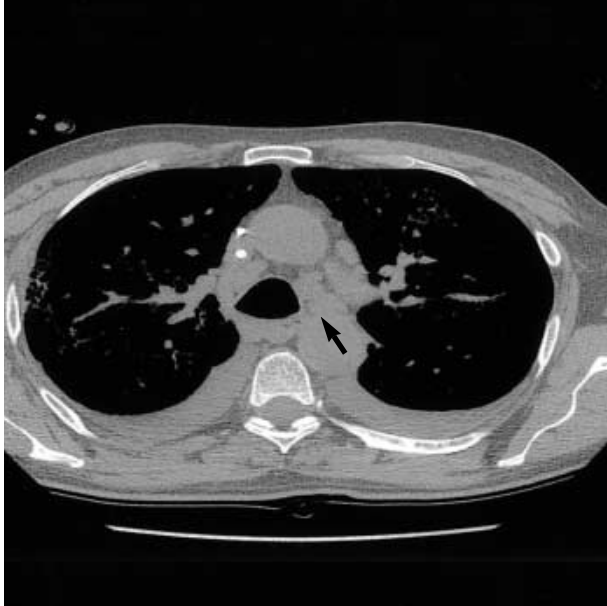

Fig. 1. CT scanning shows multiple lymphadenopathies of mediastinal (subcarinal, A-P window, and left lower paratracheal) lymph nodes (arrow).

USA) was performed. The nucleus and cytoplasm was strongly positive for calretinin (Fig. 3B), which shows that these cells are mesothelial cells. During the clinical follow-up for 1 year, the patient is alive and well without any clinical evidence of mesothelial malignancy. The size of the enlarged mediastinal nodes remained unchanged, which suggest the reactive hyperplasia of lymph nodes secondary to coronary heart disease.

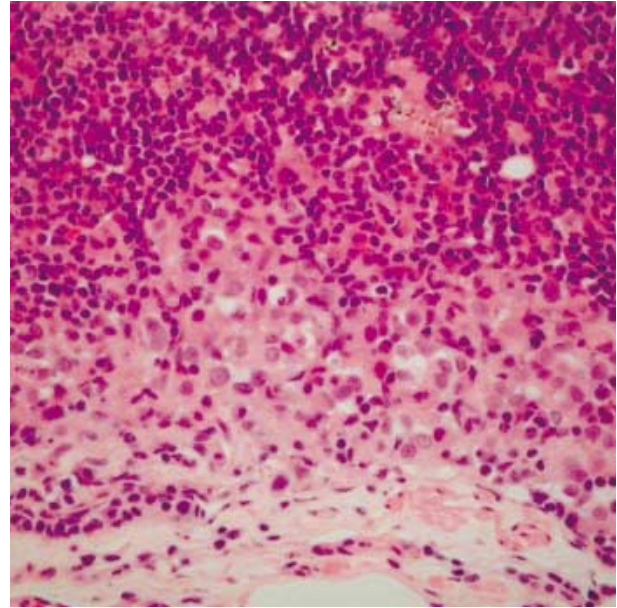


Fig. 2. Epithelioid cells are present singly or in small clusters in the subcapsular sinuses of the mediastinal lymph node.

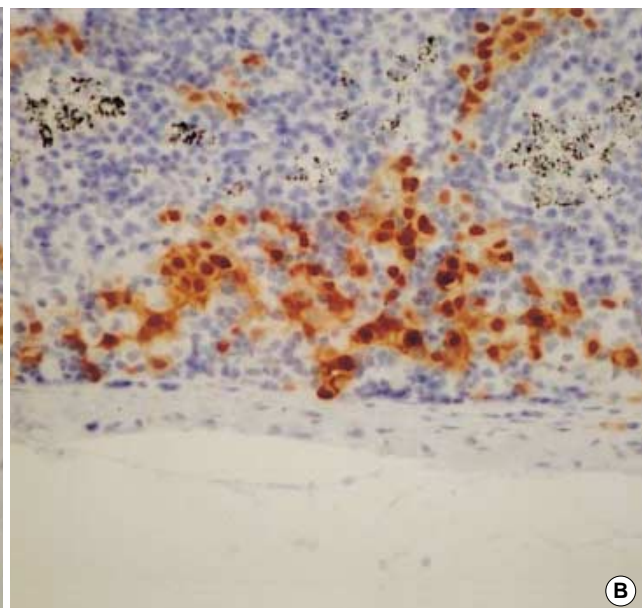
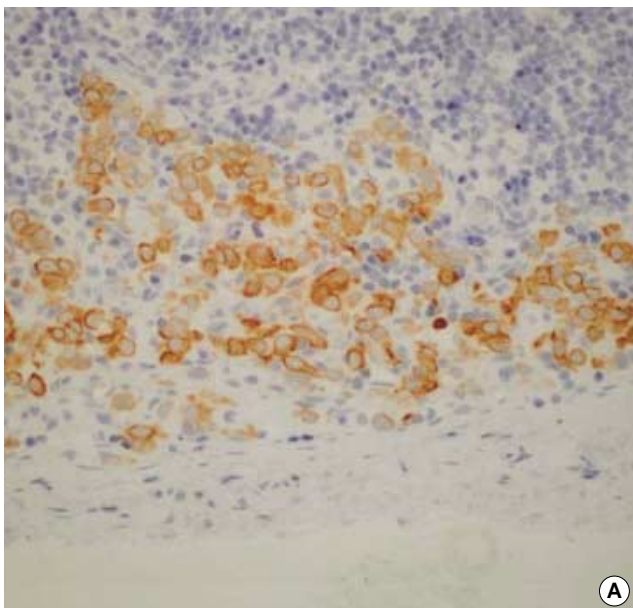


Fig. 3. These epithelioid cells are immunopositive for CK (AE1/AE3) (A) and calretinin (B), supporting these epithelioid cells being of mesothelial cell origin.

DISCUSSION

Benign inclusions in lymph nodes, either as glandular or non-glandular form, are uncommon and thus occasionally mistaken as metastasis.⁷⁻⁹ The most common intranodal glandular form of inclusions is of Müllerian origin, while other inclusions such as thyroid, salivary gland, breast, pancreas, renal tubules, urothelium, and colon are much rarer. These inclusions are typically associated with the lymph nodes in the proximity to the glandular organ of origin. Non-glandular inclusions such as nevus cells, decidua, mesothelial cells, and leiomyomatosis are much less common.

Two possible modes of histogenesis have been postulated for these aberrant intranodal inclusions.¹⁰ The most likely explanation for most Müllerian-type, thyroid, salivary gland, breast, and pancreatic inclusions is the entrapment of the remnant cells during embryonic development. The other possible mode is the transportation of benign inclusions through the lymphatics to the lymph node during injury or manipulation at the primary site of the origin. This mode of access is the favored explanation for colonic glands, renal epithelium, urothelium, nevus, and endometriosis. Lymphatic dissemination may be the probable route by which the mesothelial cells reach the lymph node.

Recently, benign mesothelial cell inclusions have been reported in the sinuses of the mediastinal lymph nodes.^{1,3-5} These inclusions have occurred in association with the hyperplasia and inflammation of the associated serosal membranes. Parkash *et al.*⁵ reported eight cases with benign mesothelial cells in mediastinal lymph nodes in the absence of neoplasm. They found that benign mesothelial cells are more common in the draining lymph nodes from the inflamed pleural or pericardial surfaces. Rutty and Lauder,³ using a panel of immunohistochemistry, were unable to find mesothelial cells in 318 mediastinal lymph nodes from 80 autopsy cases. These differences might be explained by the selection bias for the study. Rutty and Lauder³ did not examine the cases with inflammation of the mesothelial surfaces and also did not mention about the association with pleuritis or pericarditis. The other possibility may be that mesothelial cells in lymph nodes may not be viable for long times and that Parkash *et al.* selected these cells from intraoperative lymph nodes that were surgically removed and fixed rapidly.

It is difficult for the pathologist to distinguish mesothelial cell inclusions from sinus histiocytosis, metastatic carcinoma, or metastatic mesothelioma. Microscopically, the mesothelial

cells have the oval to round vesicular nuclei and fairly abundant eosinophilic cytoplasmic granules with so-called mesothelial windows. Immunohistochemically, these mesothelial cells are positive for cytokeratin (both AE1/AE3 and CAM5.2) and calretinin, but negative for other antibodies such as CD68, epithelial membrane antigen, Leu-M1, and carcinoembryonic antigen. This distinguishes mesothelial cell inclusions from sinus histiocytosis or metastatic carcinoma. In addition, the clinical absence of carcinoma in the primary gland of origin and the lack of cellular atypia, mitotic activity, or desmoplasia facilitate to distinguish these inclusions from metastatic carcinoma. However, there may be some overlap in clinical history and morphological characteristics between metastatic mesothelioma and mesothelial cell inclusions.¹⁰ Immunohistochemistry cannot distinguish benign mesothelial cell inclusions from malignant mesothelioma. In this situation, cytological evaluation, *p53*-immunostaining, and clinical follow-up should be considered.

In summary, we report a case of benign mesothelial cell inclusions in the mediastinal lymph node and review the literature. The possibility of mesothelial cell inclusions should be raised when the nodal changes resemble metastatic carcinoma morphologically but the primary site can not be identified clinically. And the proper use of immunohistochemical stainings including mesothelial cell markers is recommended.

REFERENCES

1. Brooks JS, LiVolsi VA, Pietra GG. Mesothelial cell inclusions in mediastinal lymph nodes mimicking metastatic carcinoma. *Am J Clin Pathol* 1990; 93: 741-8.
2. Fisher CJ, Hill S, Millis RR. Benign lymph node inclusions mimicking metastatic carcinoma. *J Clin Pathol* 1994; 47: 245-7.
3. Rutty GN, Lauder I. Mesothelial cell inclusions within mediastinal lymph nodes. *Histopathology* 1994; 25: 483-7.
4. Argani P, Rosai J. Hyperplastic mesothelial cells in lymph nodes: report of six cases of a benign process that can stimulate metastatic involvement by mesothelioma or carcinoma. *Hum Pathol* 1998; 29: 339-46.
5. Parkash V, Vidwans M, Carter D. Benign mesothelial cells in mediastinal lymph nodes. *Am J Surg Pathol* 1999; 23: 1264-9.
6. Sussman J, Rosai J. Lymph node metastasis as the initial manifestation of malignant mesothelioma. Report of six cases. *Am J Surg Pathol* 1990; 14: 819-28.
7. Karp LA, Czernobilsky B. Glandular inclusions in pelvic and abdom-

- inal para-aortic lymph nodes. *Am J Clin Pathol* 1969; 52: 212-8.
8. Colby TV. Benign mesothelial cells in lymph node. *Adv Anat Pathol* 1999; 6: 41-8.
 9. Cohn DE, Folpe AL, Gown AM, Goff BA. Mesothelial pelvic lymph node inclusions mimicking metastatic thyroid carcinoma. *Gynecol Oncol* 1998; 68: 210-3.
 10. Vilela DS, Garcia FMI. Embolization of mesothelial cells in lymphatics: the route to mesothelial inclusions in lymph nodes? *Histopathology* 1998; 33: 570-5.