
인간 유두종 바이러스의 생물학적 특성과 종양발생과정에 대한 이해와 임상적 적용

가톨릭대학교 의과대학 강남성모병원 산부인과학교실

박 종 섭

Biology and Oncogenesis of Human Papillomavirus and Its Clinical Application

Jong Sup Park, M.D., Ph.D.

Department of Obstetrics & Gynecology, Kangnam St. Mary's Hospital,
The Catholic University of Korea, College of Medicine, Seoul, Korea

Natural History and Epidemiology of Genital HPV Infection

From the global perspective, cervical cancer is the second most common female cancer in the world, with an incidence approximating 450,000 cases per year.¹ Current evidence implicates human papillomavirus (HPV) infection as part of the natural history of cervical carcinogenesis (Fig. 1).^{2,3} Cervical neoplasia is one spectrum of disease from HPV infection through dysplasia to invasive cancer. The review of numerous epidemiologic studies of cervical cancer has shown strong associations with marital and sexual patterns.⁴ It is well established that women with multiple partners and early ages at first intercourse are at risk for cervical cancer, supporting

hypotheses regarding a vulnerable period of the cervix and a need for repeated exposure to infectious agents. Of specific interest is the independent effect of herpes simplex type 2 (HSV 2) on risk, especially given some evidence that this viral agent may interact with HPV. Other speculative risk factors for cervical cancer include cigarette smoking, oral contraceptive usage and certain nutritional deficiencies, but it is not clear whether these factors operate independently from HPV. In a widely cited paper, Lorincz et al. used the terms low-risk, intermediate-risk, and high-risk to describe the differing degrees of associated common genital HPV types with increasing degree of cervical neoplasia.⁵ More than 35 HPV types infect the genital epithelium; HPV-16 and -18 are found most frequently in cervical carcinomas (high-

책임저자 : 박 종 섭

주 소 : 서울 서초구 반포동 505번지, 가톨릭대학교 산부인과학교실 강남성모병원

전 화 : 02-590-2748

팩 스 : 02-595-8774

E-mail address : jspark@catholic.ac.kr

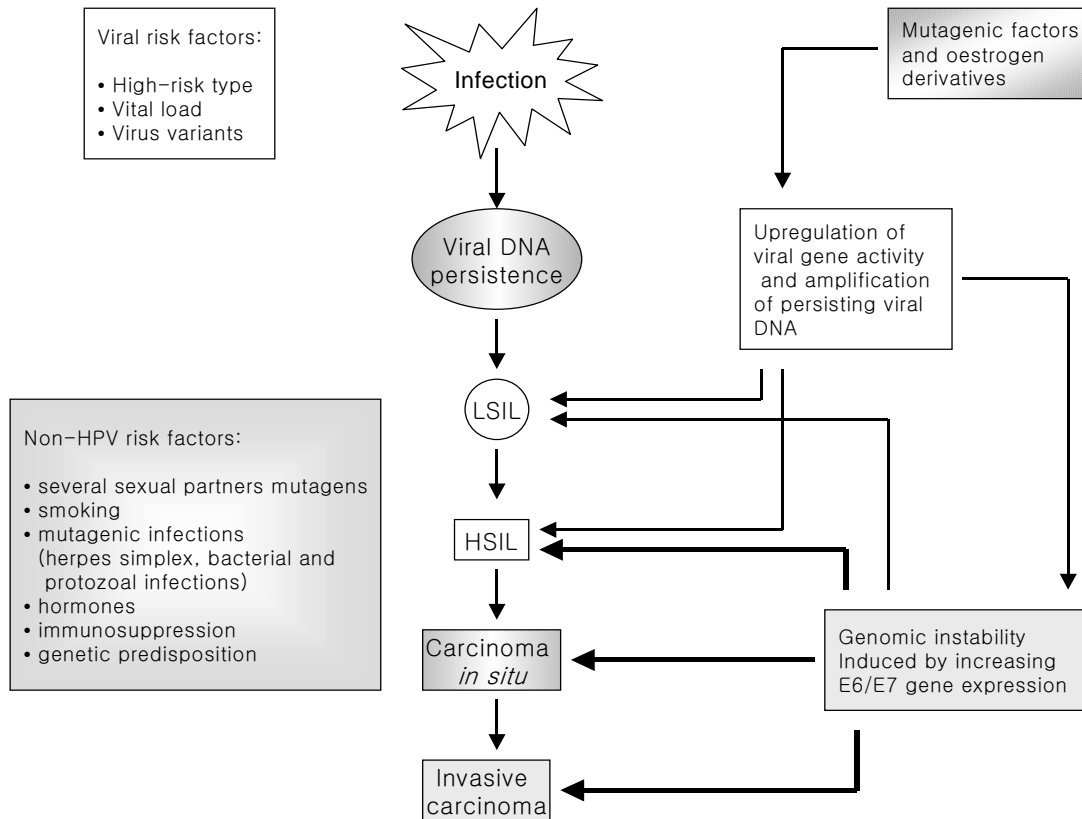


Fig. 1. Natural history of HPV-induced cervical carcinogenesis

risk) and HPV-31, -33, -35, -39, -45, -51, -52, -56, and -58 are associated with premalignant or malignant lesions (intermediate-risk). The epidemiologic studies have established a causal link between the presence of HPV types 16, 18, 31, 33, 39, 45, 51, 52, 56, and 58 and the development of invasive cervical cancers.^{6,7} The genital warts may be caused by low-risk HPV types 6, 11, 42, 43, and 44 that are virtually never found in cervical cancer. There is compelling evidence that infection with high-risk HPV types is a risk factor for persistent HPV infection.^{8,9} However, the clinical outcome of these specific HPV types in cervical lesions remains to be established. Some cases of cervical dysplasia are believed to progress to cervical cancer, but the majority of mild lesions spontaneously regress. Individuals with high-risk type-specific persistent infection have a higher risk of persistent SIL (squamous intraepithelial lesion) than those with low-risk type infection (Table 1).

Table 1. Human papillomavirus types in cervical lesions

Type of cervical lesion	HPV types
Condyloma acuminata	6, 11 , 42, 43, 44, 51, 53, 83
Intraepithelial lesion	16, 18, 31, 33, 35, 39, 40, 45, 52, 58, 66, 68
Cervical cancer	16, 18, 31, 33, 35, 39, 40, 45, 51, 52, 56, 58

• HPV types with bold letters are the common types in that cervical lesion.

High-risk HPV types, particularly HPV-16, are widespread within all human populations. Infection is commonly transmitted by sexual contact and results in squamous intraepithelial lesions in women. HPV-16 is the predominant type in the cervical cancer specimens from most of all countries and HPV-18 is the frequent type found in adenocarcinomas. The proportions of the detected HPV-16 in Korean women were 8% in women

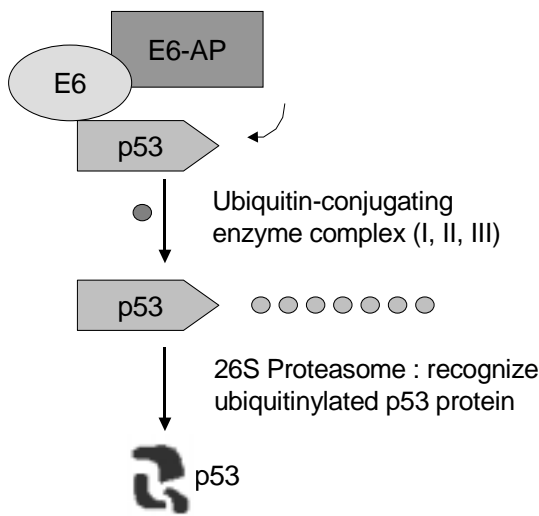


Fig. 2. Interaction of p53 and high-risk HPV E6 protein results in degradation of p53

with normal cytology, 24% (16/68) for the patients with LSIL, 33% (17/51) for HSIL, and 76% (47/62) for those with cervical cancer. It was noted that detection rates of HPV-16 increased significantly in accordance with advancing the severity of cervical lesions.¹⁰ High-risk HPV types encode two oncoproteins, E6 and E7, which inactivate the function of the p53 and retinoblastoma tumor suppressor proteins and, which have been shown to immortalize and transform cervical epithelial cells in vitro.^{11, 12} The interaction between p53 and a high-risk HPV E6 protein results in the rapid degradation of p53 through the ubiquitin-mediated proteolysis pathway (Fig. 2). The E6/E6-AP complex acts as a ubiquitin ligase and plays a direct enzymatic role in the ubiquitination reaction of p53.¹³ HPV E7 protein can disrupt pRb/E2F complex and the overexpression of E2F leads to cell cycle progression and morphological changes characteristic of cellular transformation (Fig. 3).¹⁴

The loss of pRb function at the level of the pRb gene product by protein-protein interaction with high-risk type HPV E7 might result in the release of p16^{INK4a} gene from negative transcriptional feedback control.¹⁵ p16^{INK4a} gene was overexpressed in advanced cervical dysplastic lesions and cancers, whereas no p16 expression was observed in normal squamous epithelium of the cervical mucosa.

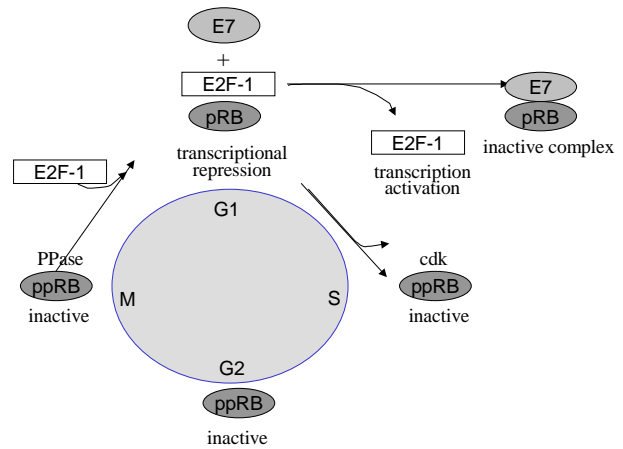


Fig. 3. HPV E7 protein disrupts pRb/E2F complex and overexpression of E2F leads to cell cycle progression.

Therefore, the restricted expression pattern of p16^{INK4a} in cervical dysplasia and cancers fulfils the criteria for specific biomarkers, indicating the aberrant expression of viral oncogenes in replication competent epithelial stem cells and marking those cells which have undergone the activation of the mutagenic process, which initiates and promotes outgrowth of cervical cancer.¹⁶ In general, HPV DNA is present as an episomal form in cervical intraepithelial lesions and the principal form of the viral DNA in invasive cancers is integrated into the host genome. When the HPV DNAs are integrated into the cellular chromosome, generally some part of the E2 ORF is lost, which release suppression of the induction of E6 and E7 mRNA expression and inactivating tumor suppressor gene products, resulting in uncontrolled cellular growth and malignant transformation.¹⁷

Most of HPV-infected cervical lesions are cleared 6-12 months after appearance probably due to immunological intervention. A small percentage persists and progresses to high-grade SIL, carcinoma *in situ*, and cancer after long latency period. The factors that determine viral persistence in some women are not completely determined. At the aspect on the viral-risk factors, high-risk type, viral load, and viral variants could affect on viral persistence in cervical carcinogenesis.¹⁸ Both high-risk and low-risk type HPVs have to stimulate G1 progression and S-phase entry for successful replication of their genome. The functional

inactivation of p73, a homologue of p53 tumor suppressor protein, by both high-risk and low-risk HPV E6 could play an important role in malignant transformation and benign condyloma formation.¹⁹ Unlike p53, p73 could be inactivated by low-risk type HPV E6 protein. This result suggests that p73 is unlikely to be a true tumor suppressor, but is rather a growth regulator possibly involved in the formation of genital condyloma. The differences in biological properties of HPV proteins from high-risk and low-risk viruses are the interaction of the E7 proteins with the Rb proteins, where the affinity of binding of the oncogenic E7 is greater than the non-oncogenic protein, or the E6 protein from high-risk viruses can bind and degrade p53 more efficiently than the E6 protein from low-risk viruses. However, most cervical lesions containing high-risk HPVs do not progress to invasive cervical cancers, implicating other cofactors in those rare cases where progression occurs. Non-HPV risk factors related to the persistence of viral DNA, might be resulted from the immunologic suppression, modification of specific cellular genes, syncarcinogenic effects of chemical and physical carcinogens, and the genetic.¹⁸ The escape of HPV-linked CIN and cervical cancer from immunologic control system seems to be based on different modifications of cellular antigen-presenting system, which might involve the transportation system and the recognition system.^{20,21}

Histological and Cytological Classification of Cervical Precancers

Currently employed histologic and cytologic classification systems have evolved over the last 100 years, before the appreciation of the importance of HPV in cervical pathology. It is now clear that the virus is important because of the morphological changes associated with viral infection and the developmental cause of cervical neoplasm (Fig. 4). The employed histologic and cytologic classification systems of cervical precancers are based on the assumption that squamous carcinoma is preceded by an *in situ* phase. This assumption followed the observation that the cervical epithelial cells and those next to invasive squamous carcinoma morphologically

resembled each other.^{22,23} Examination of cervical cytology dates from the time when Papanicolaou used vaginal aspirates to detect cells from invasive asymptomatic cervical cancer.²⁴ The death rate from cervical cancer has dropped significantly in the last 50 years. This decrease is attributed largely to the widespread use of the Papanicolaou test. Pap cytology smears are composed of five class system; Class I: absence of atypical cells, Class II: atypical, but non-malignant cells, Class III: atypical cells, suggestive of malignant cells, Class IV: cells strongly suggestive of malignancy, and Class V: changes consistent with malignancy. In the early 1950s, the term dysplasia was introduced by Reagan to designate epithelial changes less extensive than those of carcinoma *in situ*.²⁵ The term was further defined at the Committee on Histological Terminology (1962) as "all other disturbances of differentiation in the squamous epithelial lining of the glands or covering of the surface" that do not meet the criteria of CIS, being defined as a full thickness layer of undifferentiated cells in the absence of invasion.²⁶ Richart proposed the new "cervical intraepithelial neoplasia (CIN) histological classification, based on the concept that "although some mild dysplastic lesions regress spontaneously, the vast majority of dysplasias ultimately evolve to carcinoma *in situ*, and invasive carcinoma".²⁷ This system advocates that mild, moderate and severe dysplasia/CIS represent a morphological, and biological continuum of progressive and consecutive stages in the development of invasive cancer (Fig. 4).

The Bethesda System (TBS) for reporting cytology and histology was introduced in 1988 as an attempt to standardize Pap smear reporting and solve the problem of inter- and intra-pathologist reproducibility for the diagnosis of mild, moderate, and severe dysplasia and inability to specify prognosis accurately.²⁸ The Bethesda classification system improved reproducibility of diagnosis by advocating that HPV-related changes, *i.e.*, koilocytosis and CIN 1 be merged into a single category designated low-grade SIL, and that CIN 2 and CIN 3 be merged into a single category designated high-grade SIL. TBS was established by the concept of dual classification system encompassing both HPV virology and disease. Treatment has come into issues over the past few years due to

Papanicolaou 1968	Pap I	Pap II	Pap III			Pap IV	Pap V
Regan et al. 1953	Normal	HPVI	Dysplasia			CIS	Cancer
			Mild	Moderate	Severe		
Richart 1968	Normal	HPVI	CIN 1	CIN 2	CIN 3		Cancer
TBS 1988	Normal	ASCUS low-grade SIL		High-grade SIL			Cancer

ASCUS : atypical squamous cells of undetermined significance
 SIL : squamous intraepithelial lesion
 HPVI : human papillomavirus infection

Fig. 4. Cytologic and histologic classification of cervical neoplasia

greater understanding of the role of HPV in cervical carcinogenesis and the resulting changes in the terminology of cervical cytology report. HPV type may influence regression or persistence of low-grade lesions, with those associated with low-risk HPV types more likely to regress and those containing high-risk HPV types more likely to persist or progress. TBS reflects recent knowledge pertaining to the almost certain etiological role of HPV in the pathogenesis of cervical cancer and the seemingly different natural histories of low- versus high-grade intraepithelial lesions.²⁸

Three years after the introduction of TBS, the second Bethesda workshop was held to set or amend diagnostic criteria for each categories of TBS.²⁹ In addition to the revisions of the original version of TBS, it was recommended that criteria for specific diagnostic entities used in TBS, as well as criteria for specimen adequacy, be formulated. Discussions at the second workshop also emphasized the desirability of guidelines for the management of low-grade cervical abnormalities. The Interim Guidelines for Management of Abnormal Cervical Cytology, developed at a National Cancer Institute sponsored workshop,³⁰ outlined several options for follow-up of ASCUS (and LSIL) including: (a) follow-up by repeated smears every 4 to 6 months for 2 years until there have been three consecutive negative smears; (b) colposcopy may be considered if the patient is considered at high-risk, if another abnormal smear is reported in the follow-up period, or if poor compliance with option is anticipated; (c) if ASCUS is associated with severe

inflammation and a specific infectious agent is identified, reevaluation should be performed after appropriate treatment; (d) if ASCUS is associated with atrophy, repeat smear should follow a course of estrogen therapy. Ancillary diagnostic techniques such as HPV typing may be helpful in identifying women who harbor occult HSIL at the time of the ASCUS diagnosis or possibly in predicting which low-grade lesions will progress over time to HISL.

The third Bethesda workshop was held in 2001.³¹ The goals of this workshop were to promote more effective communication, to clarify in reporting cervical cytopathology results to clinicians, and to provide the information to make appropriate decision about diagnosis and treatment. The 2001 revision of the terminology was developed through a process designed to incorporate new scientific data and encourage input from a broad range of individuals involved in cervical cancer screening. Terminologies confusing clinicians and providing no additional information regarding patient management was deleted and any information related to the patient management was encouraged to add. Although the category 'Benign reactive change' was deleted, the organisms or reactive changes can be listed in the descriptive diagnoses. The terminologies of ASCUS and AGUS were changed to atypical squamous cells and atypical glandular cells, respectively. Management guidelines for women with abnormal cytology results have been developed at a consensus conference sponsored by the American Society for Colposcopy and Cervical

Pathology.³² There are a number of reasons why comprehensive, evidence-based guidelines are needed for the management of women with cervical cytological abnormalities. One reason is that National Cancer Institute Workshop recently has revised the criteria used by cytologists to render certain cytological interpretations, as well as the terminology used for reporting cervical cytology results (ie, TBS). Other reasons include a better understanding of the pathogenesis and natural history of HPV and cervical cancer precursors, and the availability of data from the National Cancer Institute's randomized Atypical Squamous Cells of Undetermined Significance/Low-grade Squamous Intraepithelial Lesion(ASCUS/LSIL) Triage Study (ALTS). Moreover, existing guidelines were developed before sensitive molecular methods for detecting high-risk types of HPV and liquid-based cytology methods became widely available.

The ALTS is a multicenter, randomized clinical trial designed to evaluate 3 alternative methods of management, namely, immediate colposcopy, cytologic follow-up, and triage by HPV DNA testing. ALTS have shown that cytologic interpretations of LSIL are so highly associated with HPV and that an HPV triage test is not useful.³³ LSIL cytology is best managed by colposcopy initially, because there was no useful triage strategy identified, and that the level of risk for CIN 2 or 3 warrants colposcopic evaluation. In the setting of an ASCUS interpretation, however, approximately 40-50% of the women are HPV positive. Importantly, virtually all of the occult CIN 2 or CIN 3 associated with ASCUS is found in the HPV positive fraction.³⁴ HPV triage is at least sensitive as immediate colposcopy for detecting CIN 3 among with ASCUS. Repeat cytology with colposcopic referral at an ASCUS threshold is also sensitive in detecting CIN 3 but requires repeated visits and leads to significantly more colposcopic examinations than does a single HPV test. Management of women with atypical squamous cells (ASC) depends on whether the Pap test is subcategorized as 'undetermined significance (ASC-US)' or as 'cannot exclude high-grade squamous intraepithelial lesion (HSIL) (ASC-H)'. Women with ASC-US should be managed using a program of 2 repeat cytology tests, immediate colposcopy, or DNA testing for high-risk types of HPV.

Testing for HPV DNA is the preferred approach when liquid-based cytology is used for screening. Women who are positive will be referred for colposcopy, and those who are negative will return to yearly cytology. In most instances, women with ASC-H, LSIL, HSIL, and AGC should be referred for immediate colposcopic evaluation. The ALTS trial closed the HPV test early in LSIL cytology arm because the HPV positivity rate was 82% and was not a valid discriminator in determining the presence of disease. The standard practice is to perform colposcopy to evaluate a single LSIL result. Any women with a cytologic specimen suggesting the presence of HSIL should undergo colposcopy and directed biopsy. After colposcopically directed biopsy and determination of the distribution of the lesion, ablative therapy and destruction of the entire T-zone should be performed.

HPV Testing for Triage and Screening Method of Cervical Neoplastic Lesions

Pap cytology has remarkably reduced the incidence of cervical cancer by 70% to 80% in most countries with cytology screening programs. But, one of the major problems is that the Pap has poor sensitivity and has to be repeated frequently to protect against development of cervical cancer. The false negative rate of cervical cytology attributed to a combination of inadequate specimen collection, problems inherent in sampling small or inaccessible lesions, and errors in the microscopic reading of the cytologic specimen. The cervical brushes provide a great yield of endocervical cells, compared with the previously used cotton swabs. Technical efforts to improve cytologic evaluation have centered on the application of monolayer techniques for specimen preparation and use of computers with image analysis and neural network capability to automatic slide screening. Sampling and preparation errors can be alleviated by using a liquid-based media to collect the cytologic sample. This technique transfers 80% to 90% of the cells to the liquid media, as compared with the only 10% to 20% transferred to the glass slide with conventional cytologic testing. This reduces the rate of unsatisfactory smears encountered with conventional cytologic testing

by 70% to 90%.³⁵ The Autopap Screening System has been approved by the U.S. Food and Drug Administration for primary screening and rescreening of samples initially read as normal. This system scans the slide and uses computer imaging techniques to analyze each field of view on the slide. Computer algorithms are then used to rank each slide on the basis of the probability that the sample may contain an abnormality. This technique has reduced the false-negative rate by 32%.³⁶

The classic model of cervical cancer prevention was primary screening with cytology, followed by diagnostic colposcopy-directed biopsy, and final treatment of cancer precursors. TBS was developed to standardize cervical cytologic reporting but has resulted in classification of a large number of minimally abnormal cytologic results. The utility of a triage test in the diagnosis of cervical cancer will depend not only on the characteristics of the test itself but also on the target population, the prevalence of disease, the screening test employed, the costs of follow-up, and patient compliance.³⁷ Some clinicians advocate extending colposcopic evaluation to a large cohort of women with "atypical squamous cells", a cytologic diagnosis indicating cellular changes that are insufficient to be diagnostic of an intraepithelial lesion. Advocates of conservative management emphasize that many low-grade lesions will regress with time and that, with follow-up by repeat Pap smears, about 15% of low grade lesions that progress to high grade lesions can be detected and treated effectively.³⁸ The introduction of HPV DNA testing and other new modalities provides more options but increased complexity in the sequence of screening, triage, diagnosis, and patient management. One of the 2001 Bethesda Forum Groups addressed the use of ancillary tests, and the most commonly used ancillary test is for HPV.³⁹ The Ancillary Testing Forum addressed 3 specific issues: (1) Reporting of HPV testing methods; Molecular results should be reported as positive or negative for HPV DNA of a certain type or class. The specific HPV types included in the assay may be listed. (2) Simultaneous reporting of Pap and HPV test results; Integrated cytologic and the molecular reporting improves communication and record keeping, facilitates pathology education, and provides ongoing quality assurance for

both the cytology and the molecular tests. (3) Reporting options for HPV test results; No specific reporting model was recommended, and additional data were deemed necessary before an optimal reporting model could be advocated.

By the American Society for Colposcopy and Cervical Pathology, adjunct testing for low- and high-risk HPV types represents an option in the triage or management of women with a cervical cytology interpretation of minimally abnormal smears.^{32,39} Advances in HPV testing have produced the accurate and reproducible HPV assay systems. Accurate HPV DNA testing could be helpful to the management of ASCUS/LSIL in 2 ways. First, the type of HPV (low-risk or cancer-associated) is associated with the severity of squamous intraepithelial lesions and their natural history. Secondly, the presence or absence of cancer-associated types of HPV can help predict the accuracy of the original cytologic diagnosis of equivocal and low-grade lesions. A plausible screening strategy would be to perform the HPV test as an adjuvant to the Pap smear to identify women at risk of cervical neoplasia more comprehensively (Fig. 5).⁴⁰ Previous studies of HPV DNA testing using Hybrid Capture Type II (HC-II) have resulted in adjunctive methods in women with borderline smears,^{42,43} and there is an increasing interest in HPV DNA detection for primary cervical screening.^{43,44} In developing countries with the ineffective screening due to the lack of coverage, accessibility, and effectiveness, HPV DNA testing could be considered as an alternative method for primary screening and that the Pap smear triage method for colposcopy.⁴³ In the patients with minor degree atypia on Papanicolaou smears, the detection of high-risk HPV infection was the only significant predictor of CIN 2-3.⁴⁵ The ALTS group concluded that HC-II testing for HPV DNA has greater sensitivity for the detection of CIN 3 or above and a specificity comparable to a single additional cytologic test indicating ASCUS or above.⁴¹ Women negative by both Pap and HPV testing are at the lowest risk of cervical cancer and could be screened less frequently, thus saving the healthcare system money.⁴⁶ A study for the association between a positive test for HPV DNA and the risk of the subsequent development of invasive cervical cancer showed that the

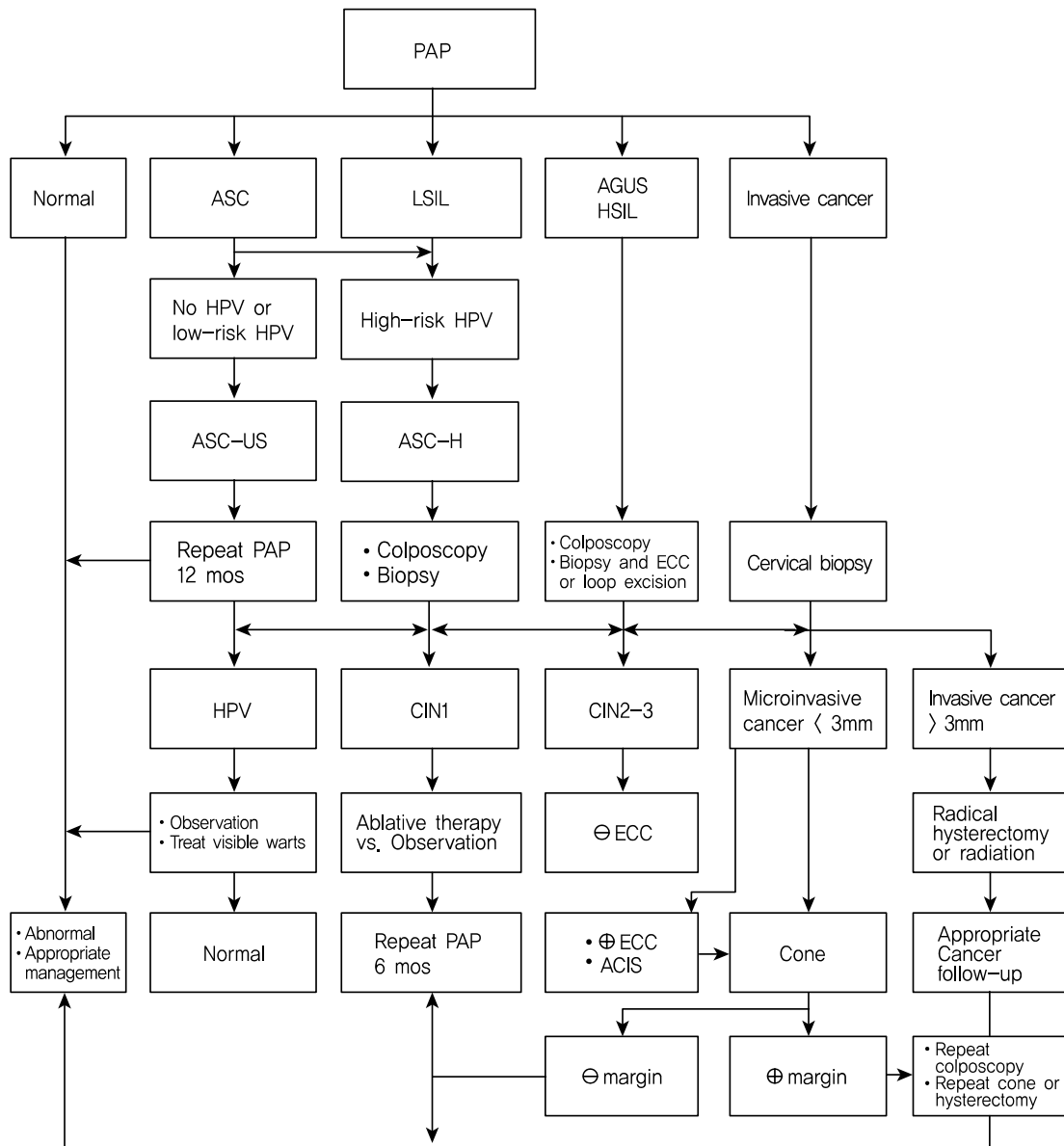


Fig. 5. Screening strategy and management protocol of cervical cytology

HPV DNA type in all women with cancer was same in the baseline smear and in the biopsy specimen. None of the control women had the same type of HPV in both smears.⁴⁷ A strong concordance between the type of HPV found in the base-line smear and that found in the biopsy specimen of the invasive cancer, further supporting the importance of viral subtyping. It would be of particular interest to know the possible differences in the clinical properties of cervical neoplasia according to HPV type. The establishment of reliable means of HPV typing for use with clinical samples of cervical neoplasia would be

an important step towards the genetic classification of HPV oncogenicity for prospective management. The HPV DNA Chip system is a newly developed biotechnology, which may be applied for detection and typing of HPV.¹⁰ HPV detection rates by HPV DNA Chip were almost comparable to those of HC-II test. Furthermore, HPV DNA chip showed great advantage, since it can discriminate HPV genotype and identify multiple infections. This may be an efficient solution for the cervical cancer prevention program, and it will eventually lead to reduce the morbidity and mortality associated with the disease.

CONCLUSION

In summary, it is clear that HPV diagnosis has a valid role for the management of the women with atypical cytology and possibly in population screening for cervical cancer. Diagnostic, therapeutic, and vaccination strategies must consider the complexity posed by the existence of at least 20 different cancer-associated HPVs in cervical neoplastic tissues. In conclusion, HPV testing of cervical specimens is a specific benefit of the new procedure in the management of cervical neoplastic lesions.

REFERENCES

1. Pisani P, Bray F, Parkin DM. Estimation of the worldwide prevalence of cancer for 25 sites in the adult population. *Int J Cancer* 2002;97:72-81.
2. Bosch FX, Manos MM, Munoz N, et al. Prevalence of human papillomavirus in cervical cancer: a worldwide perspective. International Biological Study on Cervical Cancer (IBSCC) Study Group. *J Natl Cancer Inst* 1995; 87:796-802.
3. Schiffman MH, Bauer HM, Glass AG, et al. Epidemiologic evidence showing that human papillomavirus infection causes most cervical intraepithelial neoplasia. *J Natl Cancer Inst* 1993;85:958-64.
4. Brinton LA. Epidemiology of cervical cancer overview. The epidemiology of human papillomavirus and cervical cancer. eds. Munoz N, Bosch FX, Shah KV, Meheus A. *IARC Scientific Publications*. Lyon, 1992
5. Lorincz AT, Reid R, Jensen AB, Greenberg MD, Lancaster W, Kurman RJ. Human papillomavirus infection of the cervix: relative risk association of 5 common anogenital types. *Obstet Gynecol* 1992;79:328-37.
6. De Villiers EM. Heterogeneity of the human papillomavirus group. *J Virol* 1989;63:4898-903.
7. Walker J, Bloss JD, Liao SY, Berman M, Bergen S, Wilczynski SP. Human papillomavirus genotypes as a prognostic indicator in carcinoma of uterine cervix. *Obstet Gynecol* 1989;74:781-5.
8. Ho GYF, Burk RD, Klein S, et al. Persistent genital human papillomavirus infection as a risk factor for persistent cervical dysplasia. *J Natl Cancer Inst* 1995;87:1365-71.
9. Remmink AJ, Walboomers JMM, Helmerhorst TJM, et al. The presence of persistent high-risk HPV genotypes in dysplastic cervical lesions is associated with progressive disease: natural history up to 36 months. *Int J Cancer* 1995; 61:306-11.
10. Kim CJ, Jeong JK, Park MS, et al. HPV oligonucleotide microarray-based detection of HPV genotypes in cervical neoplastic lesions. *Gynecol Oncol* 2003;89:21-7.
11. Hudson JB, Bedell M, McCance DJ, Laimins LA. Immortalization and altered differentiation of human keratinocytes in vitro by the E6 and E7 open reading frames of human papillomavirus type 18. *J Virol* 1990;64:519-26.
12. Munger K, Phelps WC, Bobb V, Howley PM, Schlegel R. The E6 and E7 genes of the human papillomavirus type 16 together are necessary and sufficient for transformation of primary human keratinocytes. *J Virol* 1989;63:4417-21.
13. Scheffner M, Huibregtse JM, Vierstra RD, Howley PM. The HPV-16 E6 and E6-AP complex functions as a ubiquitin-protein ligase in the ubiquitination of p53. *Cell* 1993;75: 495-505.
14. Arroyo M, Bagchi S, Raychaudhuri P. Association of the human papillomavirus type 16 E7 protein with the S-phase-specific E2F-cyclin A complex. *Mol Cell Biol* 1993;13: 6537-46.
15. Klaes R, Friedrich T, Spitkovsky D, et al. Overexpression of p16 INK4a as specific marker for dysplastic and neoplastic epithelial cells of the cervix uteri. *Int J Cancer* 2001;92:276-84.
16. Doeberitz MK. New molecular tools for efficient screening of cervical cancer. *Dis Markers* 2001;17:123-8.
17. Cullen AP, Reid R, Champion M, Lorincz AT. Analysis of the physical state of different human papillomavirus DNAs in intraepithelial and invasive neoplasm. *J Virol* 1991;65: 606-12.
18. zur Hausen H. Papillomaviruses and cancer: from basic studies to clinical application. *Nature* 2002;2:342-50.
19. Park JS, Kim EJ, Lee JY, Sin HS, Namkoong SE, Um SJ. Functional inactivation of p73, a homolog of p53 tumor suppressor protein, by human papillomavirus E6 proteins. *Int J Cancer* 2001;91:822-7.
20. Hopfl R, Heim K, Christensen N, et al. Spontaneous regression of CIN and delayed hypersensitivity to HPV-16 oncoprotein E7. *Lancet* 2000;356:1985-6.
21. Park JS, Kim EJ, Kwon HJ, Hwang ES, Namkoong SE, Um SJ. Inactivation of interferon regulatory factor-1 tumor suppressor protein by HPV E7 oncoprotein. Implication for the E7-mediated immune evasion mechanism in cervical carcinogenesis. *J Biol Chem* 2000;275:6764-9.
22. Cullen TS. Cancer of the Uterus, London, *Kimpton*. 1900
23. Galvin GA, Jones HW, TeLinde RW. Clinical relationship of carcinoma in situ and invasive carcinoma of the uterine cervix. *J Am Med Assos* 1952;149:744-8.
24. Papanicolaou GN. A survey of the actualities and poten-

- tialities of exfoliative cytology in cancer diagnosis. *Ann Med* 1968;30:661-74.
25. Reagan JW, Seidemann IL, Saracusa Y. The cellular morphology of carcinoma in situ and dysplasia or atypical hyperplasia of the uterine cervix. *Cancer* 1953;6:224-35.
 26. Committee for Histological Definitions. Editorial. *Acta Cytol* 1962;6:235-7.
 27. Richart RM. Natural history of cervical intraepithelial neoplasia. *Clin Obstet Gynecol* 1968;10:748-84.
 28. National Cancer Institute Workshop. The 1988 Bethesda system for reporting cervical/vaginal cytologic diagnosis. *JAMA* 1989;262:931-4.
 29. The National Cancer Institute Workshop. The Bethesda system for reporting cervical/vaginal cytology diagnoses. *Acta Cytol* 1993;37:115-24.
 30. Kurman RJ, Henson DE, Herbst A, Noller KL, Schiffman MH. Interim guidelines for management of abnormal cervical cytology. *JAMA* 1994;271:1866-9.
 31. Solomon D, Davey D, Kurman RJ, et al. The 2001 Bethesda System. Terminology for reporting results of cervical cytology. *JAMA* 2002;287:2114-9.
 32. Wright TC Jr, Cox JT, Massad LS, Twigg LB, Wilkinson EJ, ASCCP-sponsored Consensus Conference. 2001 Consensus guidelines for the management of women with cervical cytological abnormalities. *JAMA* 2002;287:2120-9.
 33. The ASCUS-LSIL Triage Study (ALTS) Group. A randomized trial on the management of low-grade squamous intraepithelial lesion cytology interpretations. *Am J Obstet Gynecol* 2003;188:1393-400.
 34. The ASCUS-LSIL Triage Study (ALTS) Group. Results of a randomized trial on the management of cytology interpretations of atypical squamous cells of undetermined significance. *Am J Obstet Gynecol* 2003;188:1383-92.
 35. Bolick D, Hellman DJ. Laboratory implementation and efficacy assessment of ThinPrep cervical cancer screening system. *Acta Cytol* 1998;42:209-13.
 36. McQuarrie HG, Ogden J, Costa M. Understanding the financial impact of covering new screening technology: the case of automatic Pap smears. *J Reprod Med* 2000;45:898-906.
 37. Solomon D. Role of triage testing in cervical cancer screening. *J Natl Cancer Inst Monogr* 2003;31:97-101.
 38. Richart RM, Wright TC Jr. Controversies in the management of low-grade cervical intraepithelial neoplasia. *Cancer* 1993;71:1413-21.
 39. Raab SS. Human papillomavirus reporting; impact on Bethesda cytology report. *Arch Pathol Lab Med* 2003; 127: 969-72.
 40. American Society of Cytopathology. Cervical cancer cytology practice guidelines. *Acta Cytol* 2001;45:201-26.
 41. Solomon D, Schiffman M, Tarone R. ALTS Study group. Comparison of three management strategies for patients with atypical squamous cells of undetermined significance: baseline results from a randomized trial. *J Natl Cancer Inst* 2001;93:293-9.
 42. Nobbenhuis M, Walboomers JMM, Helmerhorst TJM, et al. Relation of human papillomavirus to cervical lesions and consequences for cervical cancer screening: a prospective study. *Lancet* 1999;354:20-5.
 43. Cuzick J, Beverley E, Ho L, et al. HPV testing in primary screening of older women. *Br J Cancer* 1999;81:554-8.
 44. Schiffman MH, Herrero R, Hildesheim A, et al. HPV testing in cervical cancer screening; results from women in a high-risk province of Costa Rica. *JAMA* 2000;283:87-93.
 45. Shlay JC, Dunn T, Byers T, Baron AE, Douglas JM Jr. Prediction of cervical intraepithelial neoplasia grade 2-3 using risk assessment and human papillomavirus testing in women with atypia on Papanicolaou smears. *Obstet Gynecol* 2000;96:410-6.
 46. Mandelblatt JS, Lawrence WF, Womak SM, et al. Benefits and costs of using HPV testing to screen for cervical cancer. *JAMA* 2002;287:2372-81.
 47. Wallin KL, Wiklund F, Angstrom T, et al. Type-specific persistence of human papillomavirus DNA before the development of invasive cervical cancer. *N Engl J Med* 1993;341:1633-38.