대한세포병리학회지 제 16 권 제 1 호
The Korean Journal of Cytopathology
16 (1) : 25-30, 2005
ISSN 1017-0391

유방의 거짓혈관종모양 버팀질증식의 세포소견
-1예 보고-

부산대학교 의과대학 병리학교실

이 진 숙 · 김 지 연 · 신 동 훈 · 박 도 윤 · 최 경 운 · 이 창 훈 · 설 미 영

= **Abstract** =

Cytologic Features of Pseudoangiomatous Stromal Hyperplasia of the Breast
- A Case Report with Review of Literature-

Jin Sook Lee, M.D., Jee Yeon Kim, M.D., Dong Hoon Shin, M.D., Do Youn Park, M.D., Kyung Un Choi, M.D., Chang Hoon Lee, M.D., and Mee Young Sol, M.D.

Department of Pathology, College of Medicine, Pusan National University, Busan, Korea

Pseudoangiomatous stromal hyperplasia (PASH) was initially described by Vuitch et al. as a benign breast lesion, consisting of mammary stromal proliferations which simulate vascular lesions, and which might be mistaken for a low-grade angiosarcoma. This condition occasionally presents as a palpable mass in postmenopausal women, but is more frequently encountered as an incidental component in premenopausal women. Clinical, radiological, and fine-needle aspiration (FNA) findings associated with this condition can mimic those observed in conjunction with a phyllodes tumor or a fibroadenoma. The cytological features of PASH are generally nonspecific, and its diagnosis by FNA cytology is fairly difficult. In this study, we report a case of PASH, manifesting as a palpable mass

Key words: Breast, Pseudoangiomatous stromal hyperplasia, Phyllodes tumor, Fibroadenoma, Fine needle aspiration cytology

논문접수 : 2004년 12월 16일
게재승인 : 2005년 4월 22일

책임저자 : 김 지 연
주 소 : (602-739) 부산시 서구 아미동 1가 10번지, 부산대학교 의과대학 병리학교실
전 화 : 051) 240-7422
팩 스 : 051) 240-7579
E-mail address : artinus2000@hanmail.net

INTRODUCTION

Pseudoangiomatous stromal hyperplasia (PASH) was initially described in 1986 by Vuitch et al.,[1] as a benign breast lesion consisting of mammary stromal proliferations which simulate vascular lesions, and which might easily be mistaken for a low grade angiosarcoma.[2] This condition sporadically manifests itself as a palpable mass in postmenopausal women, but is far more frequently encountered as an incidental component in premenopausal women. Clinical, radiological, and fine-needle aspiration (FNA) findings associated with this condition can mimic those normally associated with a phyllodes tumor or a fibroadenoma. The nature of PASH remains unknown, but it has been suggested that PASH might constitute a neoplastic process of myofibroblastic origin.[2-4] Detailed descriptions of the cytological findings associated with PASH are fairly rare, and only eight such descriptions have been reported in the literature.[5-7] Furthermore, none of these cases have been correctly diagnosed according to the cytological evidence. The cytological features of PASH are typically nonspecific, and the diagnosis of this condition by FNA cytology is often difficult. In this study, we report a case of PASH manifesting as a palpable mass. However, the cytological diagnosis indicated a phyllodes tumor, due to the observation of abundant and hypercellular stroma.

CASE

A 58-year-old woman was followed up at our hospital for hypertension, and presented with a palpable mass in her left breast, which had persisted for three months prior to her visit. Her medical history included pulmonary tuberculosis and chronic gastritis. The patient had no personal history of trauma, nor did she have a family history of breast cancer. Physical examination revealed a nontender, firm, and movable mass in the left breast. Ultrasonography of the breast revealed a 2cm, well-defined, hypoechoic mass. We conducted FNA using a 23G needle. Six weeks after the aspirates had been reviewed, we performed a mammotome biopsy.

Cytologic Findings

The aspirates were moderately cellular, and consisted of a mixture of cohesive groups of benign ductal epithelia and abundant stromal fragments with spindle cells, in a background of single bipolar naked nuclei. We noted monolayer sheets of bland ductal epithelium, small to medium in size, which featured large and non-branching shapes, reminiscent of those seen in phyllodes tumors or fibroadenomas. The remainder of the aspirate evidenced smaller, regular gland-like clusters, as well as some scattered single epithelial cells (Fig. 1). The

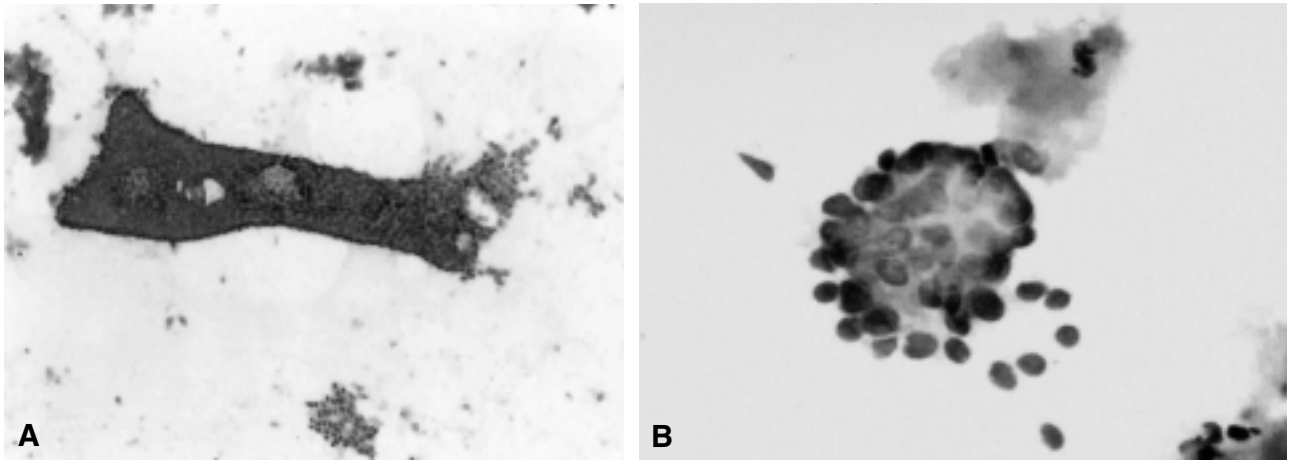

Fig. 1. FNAC findings. (A) Smear shows large, nonbranching monolayered ductal epithelium. (Papanicolaou) (B) A small gland-like cluster is seen. (Papanicolaou)

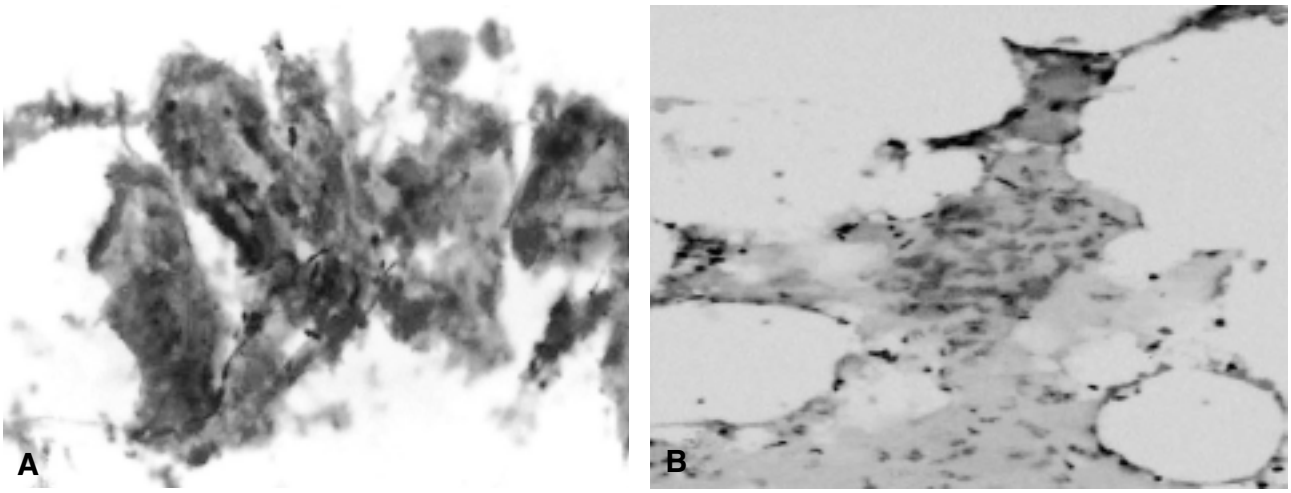

Fig. 2. FNAC findings. Hypocellular nonfibrillar stromal fragment (A) or hypercellular stromal fragment with loose stromal material (B) is seen. (Papanicolaou)

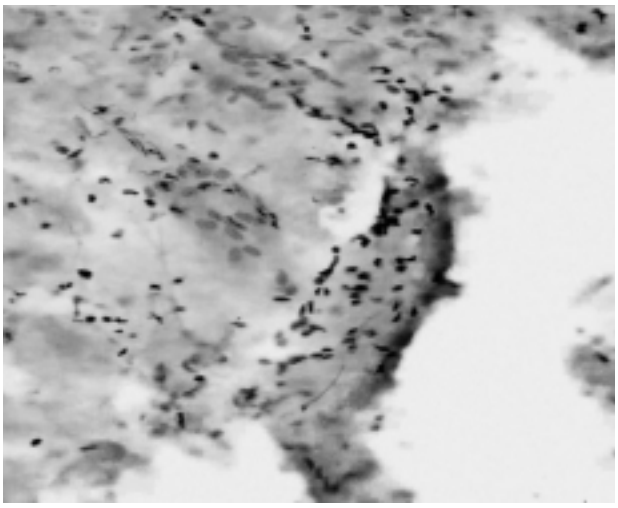

Fig. 3. High power view of FNAC findings. Dispersed stromal cells have spindle, elongated nuclei of vesicular chromatin pattern and smaller dense oval nuclei. (Papanicolaou)

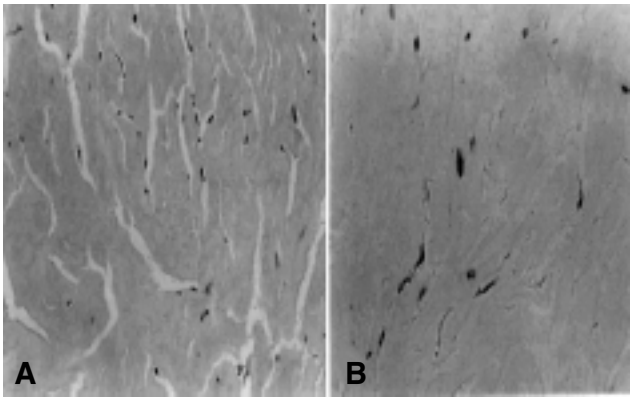

Fig. 4. Histologic findings. (A) Slitlike spaces are lined with spindle-shaped cells. (B) The spindle cells are strongly immunoreactive to CD34

dispersed stromal cells possessed spindled, elongated nuclei, which exhibited a vesicular chromatin pattern, or smaller, dense, oval, bare nuclei (Fig. 2). Some of these spindled cells contained small amounts of cytoplasm. The abundant stromal fragments were irregular in size and shape, and appeared to be composed of nonfibrillar fibrous tissue with hypocellular spindle cells (Fig. 3). After carefully considering the clinical, radiological and cytological findings, we settled on a diagnosis of stromal cell proliferative lesion, consistent with a phyllodes tumor.

Histologic Findings

The histopathology of the excised specimen revealed a pattern characteristic of PASH. In the hematoxylin and eosin-stained sections of the paraffin-embedded tissue, the tumors consisted of intermixed stromal and epithelial elements. The fibrous stroma contained a number of anastomosing slit-like spaces, some of which were compressed and others containing discernible lumina. The space was lined with spindle cells, which were reminiscent of endothelial cells (Fig. 4A). The cells bordering these spaces were discontinuous and flat, and exhibited

Table 1. Clinical and cytologic features of reported patients with PASH

Case	Age	Cellularity	Atypia	Stroma	Naked nuclei	Cytologic diagnosis
1[5]	20	Moderate	Absent	Mild	Moderate	Fibroadenoma
2[5]	42	Moderate	Mild	Minimal	Abundant	Fibroadenoma
3[5]	51	Moderate	Minimal	Moderate	Moderate	Fibrocystic disease
4[5]	51	Moderate	Absent	Absent	Moderate	Fibroadenoma
5[5]	24	Minimal	Absent	Absent	Mild	Fibroadenoma
6[5]	39	Moderate	Moderate	Minimal	Moderate	Suspicious for malignancy (carcinoma)
7[6]	34	Moderate	Absent	Moderate	Moderate	Phyllodes tumor
8[7]	41	Moderate	Absent	Mild	Moderate	Fibroadenoma
9[9]	24	Low	Mild	Minimal	Rare	Defer to histology
10[9]	50	Low	Mild	Minimal	Rare	Defer to histology
11[10]	49	Moderate	Absent	Minimal	Mild	Fibroadenoma
12[10]	56	Moderate	Absent	Minimal	Mild	Proliferative disease, consistent with clinical history of gynecomastia
13*	58	Moderate	Absent	Abundant	Moderate	Phyllodes tumor

* : our case
PASH : pseudoangiomatous stromal hyperplasia

no nuclear atypia or mitotic figures. The intervening stroma were composed of dense collagen, but also exhibited focal myxoid degeneration. The results of an immunohistochemical study showed that the lining cells were positive for vimentin (Zymed, San Francisco, California), smooth muscle actin (DAKO, Glostrup, Denmark), and CD34 (Becton Dickinson, San Jose, California)(Fig. 4B), and were negative for factor VIII (Zymed, San Francisco, California).

DISCUSSION

PASH is a benign proliferative lesion occurring in the mammary stroma, which exhibits myofibroblastic differentiation in premenopausal women.[1] PASH is histologically characterized by the presence of anastomosing, slit-like spaces, which are lined with spindle-shaped cells, and are embedded in an abundance of fibrous stroma. The accurate identification of this condition is important, as it can easily be confused with a malignant mesenchymal tumor of the breast, such as a low-grade angiosarcoma or a malignant phyllodes tumor.[1,5] The histogenesis of PASH remains a subject of some controversy. Fisher et al.[8] suggested, in 1992, that PASH was properly classed as a variant of a breast hamartoma. However, Powell et al.[4] asserted that the cellular proliferation and staining qualities inherent to the condition more accurately indicated a myofibroblastic proliferation.

To the best of our knowledge, only a few published studies in the literature address the cytological features of PASH. In all reported cases, however, the cytological findings have been similar, although there has been some variation in the reported stromal cellularity. These data are summarized in Table 1.

The cytological pattern of PASH is largely benign, and can be readily recognized on FNA materials. However, the cytological pattern of PASH is non-specific. The aspirates normally reveal monolayer sheets of bland ductal and myoepithelial cells, small to medium in size, in a background of bipolar, naked nuclei, which are associated with stromal fragments. In most cases, the epithelial component of PASH consists of monolayer

sheets, small to medium in size, and composed of two-dimensional ductal epithelium, in contrast to a fibroadenoma, which features typical elongated, canalicular, slit-like ductal structures. In our case, the observed epithelial components were reminiscent of PASH.

However, in some cases of PASH, stromal fragments have not been noted, as reported by Vicandi et al.[5] However, hypocellular and hypercellular stromal fragments containing spindle cells were particularly abundant in our case. Many other cases have also involved variable amounts of stromal fragments. Most of these fragments exhibit hypocellular spindle cells, but some are hypercellular. A recent histological study of PASH reported a spectrum of stromal changes, ranging from those classically associated with PASH to more proliferative lesions, along with the formation of cellular bundles which generally obscured the underlying PASH architecture.[4] These cellular forms of PASH can be confused with other entities which exhibit increased stromal cellularity, including phyllodes tumors and myofibroblastomas.[5] With regard to differential diagnosis from phyllodes tumor, PASH is associated with numerous hypocellular stromal fragments, and relatively less proliferative ductal epithelium. Our FNA smear revealed a few hypercellular stromal fragments in a background of abundant, fibromyxoid, stromal fragments. These cytological features indicated the diagnosis of a suspicious phyllodes tumor. On the review of the smear, the stroma exhibited a typical PASH pattern. Therefore, these stromal fragments, in addition to the dispersed bipolar cells, were thought to represent the characteristic cytological features of PASH.

Due to the absence of specific cytological features, and given the rarity of hypocellular spindle cells in this lesion, it was difficult to establish a definite diagnosis of PASH simply on the basis of the cytology. In most cases, this condition has been diagnosed as a benign lesion, usually either a fibroadenoma or a phyllodes tumor. Only one of the Vicandi cases was not diagnosed as one of these lesions.[5] A typical biphasic pattern of moderate to high cellularity, including staghorn fragments of epithelial cells in a background of bipolar naked nuclei, favors a diagnosis of fibroadenoma rather than PASH. Round and broad epithelial fragments, a low epithelial/stromal ratio, and the presence of columnar stromal cells and multinucleated giant cells tend to favor a diagnosis of phyllodes tumor, rather than PASH.[9] The cytological diagnosis of 'suspected carcinoma' has also been established in some cases, due to the presence of some scattered discohesive atypical ductal epithelum. In our case, a diagnosis of phyllodes tumor was initially established.

PASH should be included in a differential diagnosis in cases in which the aspirate samples are moderately cellular, and contain both cellular stromal fragments and dispersed bipolar cells, regardless of whether the patient is pre- or postmenopausal. We emphasize that the presence of abundant hypocellular stromal fragments containing spindle-shaped nuclei constitutes a vital indicator for a diagnosis of PASH.

REFERENCES

1. Vuitch MF, Rosen PP, Erlandson RA. Pseudoangiomatous hyperplasia of mammary stroma. *Hum Pathol* 1986;17: 185-91.
2. Rosen PP. Rosen's Breast Pathology, 2nd ed. New York: Lippincott Willians & Wilkins, 1997;757-66
3. Anderson C, Ricci A Jr, Pedersen CA, Cartun RW. Immunocytochemical analysis of estrogen and progesterone receptors in benign stromal lesions of the breast. Evidence for hormonal etiology in pseudoangiomatous hyperplasia of mammary stroma. *Am J Surg Pathol* 1991;15:145-9.
4. Powell CM, Cranor ML, Rosen PP. Pseudoangiomatous stromal hyperplasia(PASH). a mammary stroma tumor with myofibroblastic differentiation. *Am J Surg Pathol* 1995;19: 270-7.
5. Vicandi B, Jimenes-Heffernan JA, Lopez-Pilar P, Ortega L, Viguer JM. Nodular pseudoangiomatous stromal hyperplasia of the breast:cytologic features. *Acta Cytol* 1998;42:335-41.
6. McCluggage WG, Allen M, Anderson NH. Fine needle aspiration cytology of mammary pseudoangiomatous stromal hyperplasia. A case report. *Acta Cytol* 1999;43:1147-9.
7. Spitz DJ, Reddy VB, Gattuso P. Fine-needle aspiration of pseudoangiomatous stromal hyperplasia of the breast. *Diagn Cytopathol* 1999;20:323-4.
8. Fisher CJ, Hanby AM, Robinson L, Millis RR. Mammary

hamartoma; a review of 35 cases. *Histopathology* 1992;20: 99-106.

9. Lui PC, Law BK, Chu WC, Pang LM, Tse GM. Fine-needle aspiration cytology of pseudoangiomatous stromal hyperplasia of the breast. *Diagn Cytopathol* 2004;30:353-5.
10. Ng WK, Chiu CS, Han KC, Chow JC. Mammary pseudoangiomatous stromal hyperplasia. A reappraisal of the fine needle aspiration cytology findings. *Acta Cytol* 2003;47: 373-80.