

## Adrenocortical Oncocytoma – A Case Report –

Hun-Soo Kim · Dae-Young Kang<sup>1</sup>

Department of Pathology, Wonkwang  
University School of Medicine, Iksan;

<sup>1</sup>Department of Pathology, Chungnam  
National University School of Medicine,  
Daejeon, Korea

Received : February 1, 2007  
Accepted : April 30, 2007

### Corresponding Author

Dae-Young Kang, M.D.  
Department of Pathology, Chungnam National  
University College of Medicine, 6 Munwha-1-dong,  
Jung-gu, Daejeon 301-131, Korea  
Tel: 042-580-8232  
Fax: 042-581-5233  
E-mail: dykang@cnu.ac.kr

Adrenocortical oncocytomas have rarely been reported on in the medical literature, and most of them have been nonfunctional and benign. We report here on a case of a 43-year-old man with a left abdominal mass. The patient showed no signs of hypertension or hormonal imbalance. The abdominal CT scans showed a huge mass that measured 11 cm in diameter, and it was located at the left adrenal area. Grossly, the tumor was well encapsulated and homogenous with central necrosis. Microscopically, the tumor was composed of oncocytes with abundant granular cytoplasm. Immunohistochemically, these cells were diffusely positive for cytokeratin and focally positive for synaptophysin and NSE. The ultrastructural studies showed numerous mitochondria in the cytoplasm. We will discuss the criteria that indicates malignancy as presented by Weiss *et al.* and we summarize the difference between conventional and oncocytic adrenocortical neoplasm. This case showed some features of malignancy based on the criteria presented by Weiss *et al.*

**Key Words** : Adrenal cortex neoplasm; Oncocytoma; Immunohistochemistry; Electron microscopy

Oncocytomas are relatively common in various organs such as the kidney, salivary glands and the thyroid gland.<sup>1</sup> Further oncocytomas have occasionally been reported the pituitary and parathyroid glands, lacrimal gland, respiratory tract and choroid plexus.<sup>1</sup> Oncocytoma arising in the adrenal cortex is also rare, and only about 25 cases have so far been reported on. We report here on the histopathological and ultrastructural findings of a 43 year old male who was diagnosed with adrenal cortical oncocytoma. In addition, based on the present case and our review of literature, we will discuss the pathologic criteria of malignancy as presented by Weiss *et al.*

### CASE REPORT

A 43-year-old male was admitted to Chungnam National University Hospital (CNUH) because of a huge adrenal mass that was found at a local clinic. The patient complained of left upper quadrant discomfort that he had experienced for about one month. His personal and family history was unremarkable. The patient had no previous history of hypertension or any other

signs or symptoms of high blood pressure such as dizziness, headache, palpitation and visual disturbance. He only complained of 2 kg weight loss in one-month period. The abdominal computed tomography revealed a well defined, 11 × 10 cm sized left adrenal mass with central low density. No lymphadenopathy or signs of local invasion was noted (Fig. 1). The laboratory tests including the serum potassium, VMA, the metanephrine levels and the dexamethasone suppression test were all within the normal range. The patient then underwent left adrenalectomy.

The resected specimen showed a well-encapsulated, solid mass that measured 13 cm in diameter and it was 464 g in weight. On section, the tumor was soft, homogenous and friable with central necrosis or infarction (Fig. 2).

Microscopically, the tumor consisted of oncocytic cells with abundant, eosinophilic granular cytoplasm, and the cells were arranged in a diffuse pattern (Fig. 3). Focal bizarre tumor cells with marked nuclear pleomorphism were also noted (Fig. 3, inset). There were diffuse areas of necrosis (Fig. 4) and some evidence of fibrotic bands. The mitotic figure count was 2-3/50 HPFs. There was no evidence of capsular invasion, but there were some foci of tumor cells in the vascular structures (Fig. 4,

inset). Although this feature is a subject of controversy, such a finding can contradict the benign nature of the tumor.

Immunohistochemically, the tumor cells strongly stained for cytokeratin (CK) (Dako Co., Carpinteria, CA, USA) (Fig. 5), and CK5/6 (Dako) while synaptophysin (Zymed, San Francisco, CA, USA) and neuron specific enolase (NSE) (Zymed) (Fig. 5, inset) showed only focal staining. The tumor cells were neg-

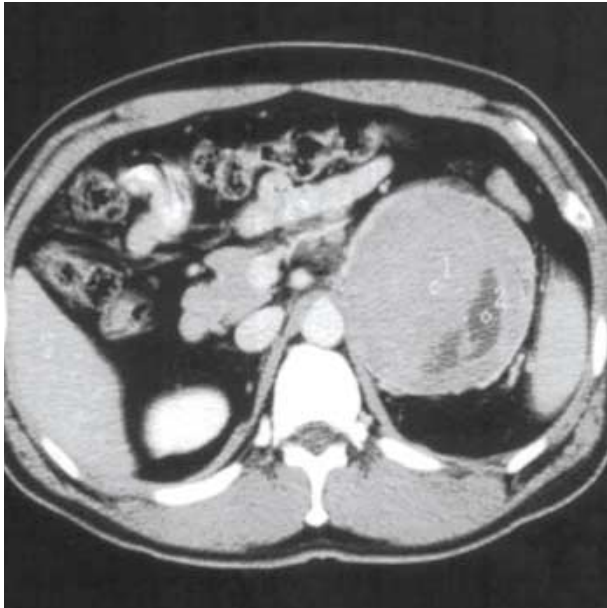

Fig. 1. Abdominal CT scan shows a well defined, isodense and homogenous left adrenal gland mass with geographic central low density lesion, measuring 11 cm in diameter.

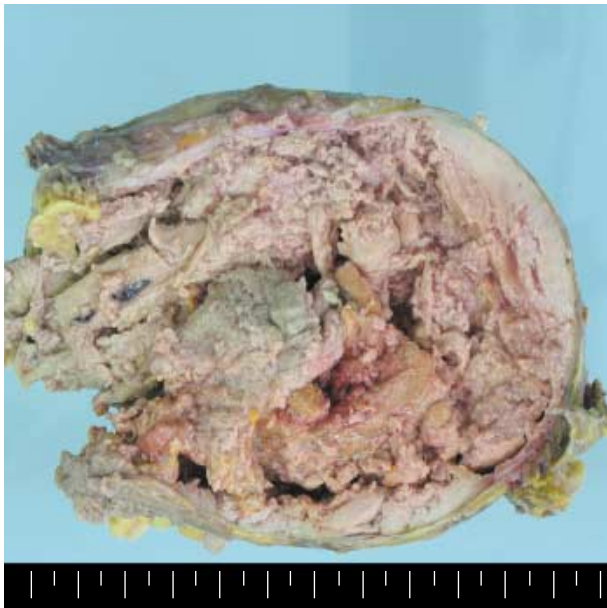


Fig. 2. The cut surface of the mass is solid, homogenous and friable with central necrosis and degeneration.

ative for S-100 protein (DiNonA Inc. Seoul Korea) and less than 5% of the tumor cells were reactive for Ki-67 (Zymed). The formalin-fixed tissue was refixed in 2.5% glutaraldehyde and this was sent for electron microscopic evaluation. The cytoplasm of the oncocytic cells showed numerous mitochondria without neurosecretory granules (Fig. 6). Some mitochondria show round osmophilic intramitochondrial inclusions (Fig. 6,

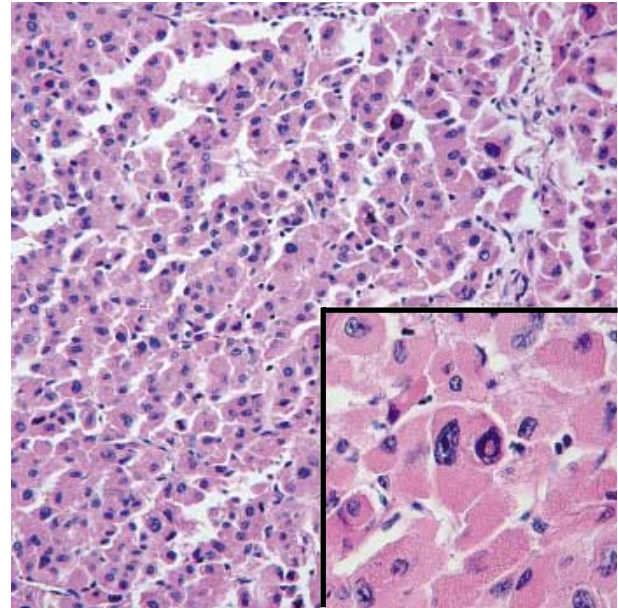


Fig. 3. Diffuse proliferation of large polygonal cells with abundant eosinophilic cytoplasm and occasional enlarged atypical nuclei (inset).

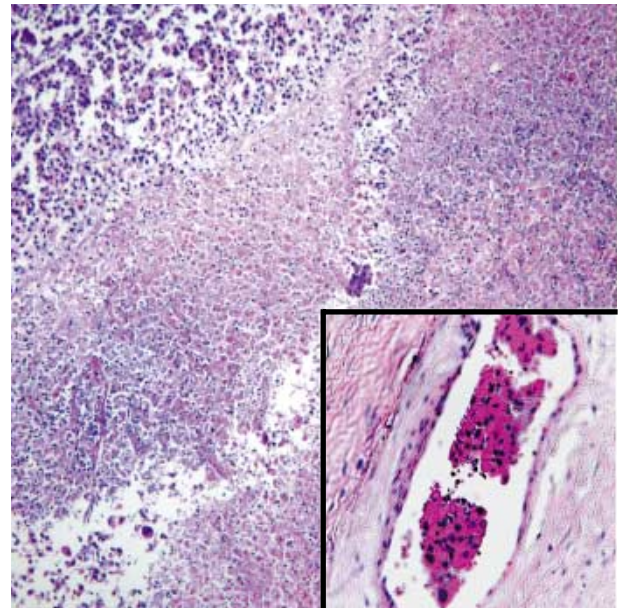


Fig. 4. Diffuse necrosis with focal suspicious areas of tumor emboli (inset).

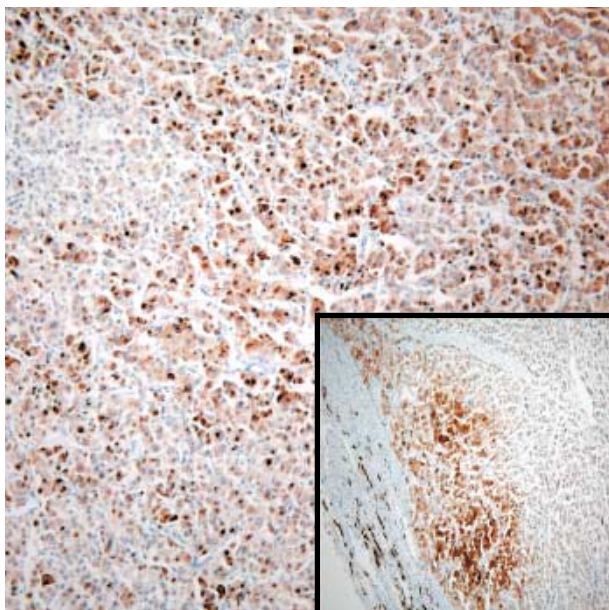


Fig. 5. Diffuse cytoplasm expression of cytokeratin and focal reactivity for neuron specific enolase (inset).

arrow). Further subsequent surgical resection post-operative chemotherapy or radiation treatment was not carried out. The patient has been doing well with no evidence of tumor recurrence at the twelve month follow-up date.

## DISCUSSION

Oncocytes are polygonal epithelial cells with abundant acidophilic, granular cytoplasm.<sup>1</sup> Electron microscopic studies showed the cytoplasm of the oncocytes are filled with numerous mitochondria.<sup>1</sup> The reason for this accumulation of mitochondria is not well established. Many investigators suggest that mitochondria are increased as a compensatory response to a functional impairment.<sup>2</sup>

The majority of the adrenocortical oncocytic tumors are non-functional and benign. Only four of these reported tumors were hormonally active. Two cases involved the sex hormones, each with virilization<sup>3</sup> and feminization,<sup>4</sup> respectively, and there have been 2 reported cases of Cushing's syndrome.<sup>5,6</sup> These reports show that this tumor is not a subtype of the hormone producing adrenocortical adenoma family, but rather, it is an independent entity and shares some common features.<sup>7</sup>

Defining the criteria for aggressive clinical behavior may be quite difficult. No single histological feature can predict the behavior of adrenocortical tumors. Numerous studies have proven that a combination of clinical, biochemical and histo-

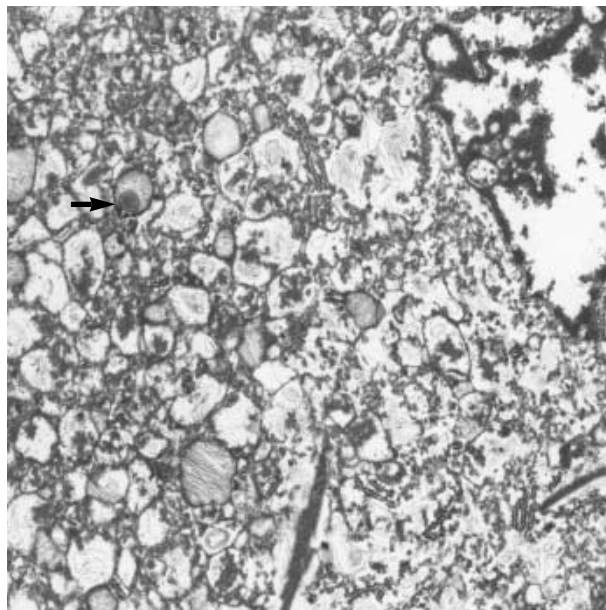


Fig. 6. The cytoplasm of the oxyphilic cells are packed with numerous mitochondria. Some mitochondria show intramitochondrial osmophilic inclusions (arrow) ( $\times 10,800$ ).

logical features can be useful to discriminate benign from malignant lesions.<sup>8,9</sup> A variety of systems have been developed to differentiate between benign and malignant adrenal cortical tumors. Among them, the so-called Weiss system proposes nine pathological features that were most commonly found in adrenocortical carcinomas. These features were high nuclear grade or atypia (Furhmann nuclear grade III-IV), more than 75% of eosinophilic tumor cell cytoplasm, more than 33% diffuse architecture, the presence of necrosis and mitotic figures of more than 5/50 HPE, atypical mitotic figures, capsular invasion, venous invasion and sinusoidal invasion. The presence of three or more of the above findings highly correlates with subsequent malignant behavior.<sup>9-11</sup> The Weiss system is reliable with a high degree of inter-observer agreement.<sup>12</sup> The definitive criteria for malignancy are local invasion and distant metastasis, and no matter how benign looking the tumor may be, this is a strong indicator of an unfavorable outcome.<sup>13</sup> A series reported by Lin *et al.* described tumors that have some features of malignancy, but cannot be concluded to be malignant, can be called 'oncocytic neoplasm of uncertain malignant potential'. These tumors had increased proliferative activity and necrosis, but no evidence of invasion.<sup>13</sup> Kurek *et al.* suggested that all oncocytic adrenocortical tumors of uncertain malignant potential should be considered as carcinomas.<sup>14</sup>

The histologic criteria that have been used for conventional adrenocortical carcinoma has also been applied for oncocytoma.<sup>9,10</sup> It is difficult to apply the Weiss system to oncocytic adrenocor-

tical neoplasm because by, definition, oncocytic adrenocortical neoplasm contains at least two histological findings associated with malignancy in the Weiss system: eosinophilic tumor cell cytoplasm and diffuse architecture. The diagnosis of carcinoma can be made only if another feature is encountered.<sup>15</sup> Thus, Lin *et al.* had a more conservative approach for oncocytic adrenocortical tumors. The diagnosis of carcinoma should be reconsidered in the absence of mitotic activity, necrosis or invasion.<sup>12</sup> Bisceglia and a group of coworkers<sup>4</sup> suggested a modified version of the Weiss system for nononcocytic tumors. The previous nine parameters were regrouped into major, minor and definitional criterion.<sup>4</sup> The major criteria consisted of a high mitotic rate, atypical mitosis and venous invasion. Any one of these features can be considered to indicate malignancy. Diffuse architecture, oncocytic or clear cytoplasm and a high nuclear grade is definitional and these features can be frequently observed in benign oncocytoma. These parameters are grouped into the definitional criteria, and they are excluded from the classical Weiss system. The remaining four parameters (large size, necrosis, capsular invasion and sinusoidal invasion) are classified into minor criteria. If a tumor exhibits any one of these features, then it is considered to have borderline or uncertain malignant potential. This new system has its limitations, but this clearly dismisses the definitional parameters defined by Weiss, and it puts a great deal of weight on the more important features leading to malignancy.<sup>11</sup>

Our case showed some features of malignancy, such as necrosis, nuclear pleomorphism and possible foci of tumor emboli in the microvasculature. Yet this case however leaves some element of doubt. The exact nature of the necrosis was unclear and it may actually have been ischemic infarction rather than true tumor necrosis, and the tumor emboli do not satisfy the criteria presented by Weiss *et al.*<sup>9,10</sup>

Other than the usual histologic investigation, more objective parameters have been sought to differentiate malignant from benign adrenocortical tumors. Among them, immunohistochemical staining for MIB-1 (Ki-67) antibody has proven to be useful in distinguishing adrenocortical adenomas from carcinomas.<sup>13,16</sup>

There are five other reported cases of adrenocortical oncocytoma in Korea.<sup>7,15,17</sup> Song *et al.* extensively reviewed the detailed clinicopathological, immunohistochemical and ultrastructural findings of four of these five cases. His analysis suggested that most oncocytic adrenocortical carcinomas should be regarded as low-grade malignancy.<sup>15</sup> These results were similar to our case, i.e. having a large size, diffuse architecture and foci of necrosis.

According to the modified Weiss criteria,<sup>4</sup> these factors highly suggested that the diagnosis of this case should be regarded as adrenocortical oncocytoma of uncertain malignant potential.

## ACKNOWLEDGMENT

This paper was supported by Wonkwang University in 2007.

## REFERENCES

1. Chang A, Harawi SJ. Oncocytes, oncocytosis and oncocytic tumors. *Pathol Annu* 1992; 27: 263-304.
2. Tallini G. Oncocytic tumours. *Virchows Arch* 1998; 433: 5-12.
3. Erlandson RA, Reuter VE. Oncocytic adrenal cortical adenoma. *Ultrastruct Pathol* 1991; 15: 539-47.
4. Bisceglia M, Ludovico O, Di Mattia A, *et al.* Adrenocortical oncocytic tumors: report of 10 cases and review of the literature. *Int J Surg Pathol* 2004; 12: 231-43.
5. Sasano H, Suzuki T, Sano T, Kameya T, Sasano N, Nagura H. Adrenocortical oncocytoma. A true nonfunctioning adrenocortical tumor. *Am J Surg Pathol* 1991; 15: 949-56.
6. Xiao GQ, Pertsemlidis DS, Unger PD. Functioning adrenocortical oncocytoma: a case report and review of the literature. *Ann Diagn Pathol* 2005; 9: 295-7.
7. Cha HJ, Suh YL, Yang JH. Adrenocortical oncocytoma: a case report. *Korean J Pathol* 1999; 33: 463-6.
8. Medeiros LJ, Weiss LM. New developments in the pathologic diagnosis of adrenal cortical neoplasms: a review. *Am J Clin Pathol* 1992; 97: 73-83.
9. Weiss LM. Comparative histologic study of 43 metastasizing and nonmetastasizing adrenocortical tumors. *Am J Surg Pathol* 1984; 8: 163-9.
10. Weiss LM, Medeiros LJ, Vickery AL Jr. Pathologic features of prognostic significance in adrenocortical carcinoma. *Am J Surg Pathol* 1989; 13: 202-6.
11. Aubert S, Wacrenier A, Leroy X, *et al.* Weiss System Revisited: A clinicopathologic and immunohistochemical study of 49 adrenocortical tumors. *Am J Surg Pathol* 2002; 26: 1612-9.
12. Lin BT, Bonsib SM, Mierau GW, Weiss LM, Medeiros LJ. Oncocytic adrenocortical neoplasms: a report of seven cases and review of the literature. *Am J Surg Pathol* 1998; 22: 603-14.
13. Vargas MP, Vargas HI, Kleiner DE, Merino MJ. Adrenocortical neoplasms: role of prognostic markers MIB-1, p53, and RB. *Am J Surg Pathol* 1997; 21: 556-62.

14. Kurek R, Von Knobloch R, Feek U, Heidenreich A, Hofmann R. Local recurrence of an oncocytic adrenocortical carcinoma with ovary metastasis. *J Urol* 2001; 166: 985.
15. Song SY, Park S, Kim SR, Suh YL. Oncocytic adrenocortical carcinomas: a pathological and immunohistochemical study of four cases in comparison with conventional adrenocortical carcinomas. *Pathol Int* 2004; 54: 603-10.
16. Hoang MP, Ayala AG, Albores-Saavedra J. Oncocytic adrenocortical carcinoma: a morphologic, immunohistochemical and ultrastructural study of four cases. *Mod Pathol* 2002; 15: 973-8.
17. Lee SJ, Lee HG, Park CY, *et al.* A case of adrenocortical oncocytoma. *J Korean Soc Endocrinol* 2004; 19: 82-9.