

## Glial Choristoma of the Middle Ear – A Case Report –

Su-Jin Kim • Dae-Cheol Kim

Department of Pathology, Dong-A  
University College of Medicine, Busan,  
Korea

Received : July 12, 2007  
Accepted : September 20, 2007

**Corresponding Author**

Dea-Cheol Kim, M.D.  
Department of Pathology, Dong-A University College  
of Medicine, 1 3-ga, Dongdaeshin-dong, Seo-gu,  
Busan 602-713, Korea  
Tel: 051-240-2878  
Fax: 051-243-7396  
E-mail: freehand@dau.ac.kr

Glial choristoma is defined as a mass that is composed of mature, normal brain tissue, isolated from the cranial cavity or spinal canal. The involvement of an extracranial non-midline location, especially the middle ear or mastoid region, is quite exceptional. We report here on a case of glial choristoma of the middle ear in a 2-year-old boy. He presented with otalgia and otorrhea that had lasted for 6 months, and radiological studies revealed a mass-like lesion with soft tissue density in the middle ear cavity. The patient underwent simple mastoidectomy and tympanoplasty. Histologically, the mass was composed of disorganized but mature, normal glial tissue with immunoreactivity for glial fibrillary acidic protein. The patient had no previous history of head trauma or surgery, and no evidence of central nervous system connection was noted on the radiological or operative findings. This mass was regarded as a primary glial heterotopia rather than an acquired encephalocele.

**Key Words** : Choristoma; Glia; Middle ear

A choristoma is the presence of histologically normal tissue that is abnormally located.<sup>1</sup> Glial choristoma or heterotopic glial tissue is defined as a mass composed of mature, normal brain tissue that's isolated from the cranial cavity or spinal canal, and usually involves an extracranial midline structure of the head and neck, such as the nose, nasopharynx, oropharynx, palate, tongue, and tonsil.<sup>2</sup> The involvement of an extracranial non-midline location, especially the middle ear and mastoid region, is extremely exceptional. A few cases have been reported, but these have been in adults, and most of them had previous history of head trauma, surgery, or chronic inflammation of the middle ear. We report here on a case of glial choristoma of the middle ear of a child who had no history of trauma or surgery.

### CASE REPORT

A 2-year-old boy presented with otalgia and otorrhea that had lasted for 6 months. The boy was healthy except for the otalgia and otorrhea lasting for 6 months, and he had no previous history of head trauma or surgery. Clinically chronic otitis media

was suspected and ventilation tube insertion was attempted, but this failed because the middle ear cavity was filled with a grayish-white soft mass. On computed tomography (CT), a mass-like lesion about 1 cm in diameter with soft tissue density, was identified in the middle ear cavity (Fig. 1). An incisional biopsy was done, but the tissue showed only dense fibrovascular tissue with focal squamous epithelium and brown pigment; this was inadequate for making a diagnosis. After two incisional biopsies, the patient underwent simple mastoidectomy and tympanoplasty. Histologically, the mass was composed of mature, disorganized glial tissue without neurons. The glial tissue showed normal cellularity without cytologic atypia or pleomorphism. Gliosis or an inflammatory response was not identified (Fig. 2). The mass showed diffuse, strong immunoreactivity for glial fibrillary acidic protein and S100 protein.

On the radiological and operative findings, no evidence of central nervous system connection was noted, and there was no CSF leakage at the operation. At the 18th month of postoperative follow-up, the patient was healthy with no symptoms suggesting meningitis.

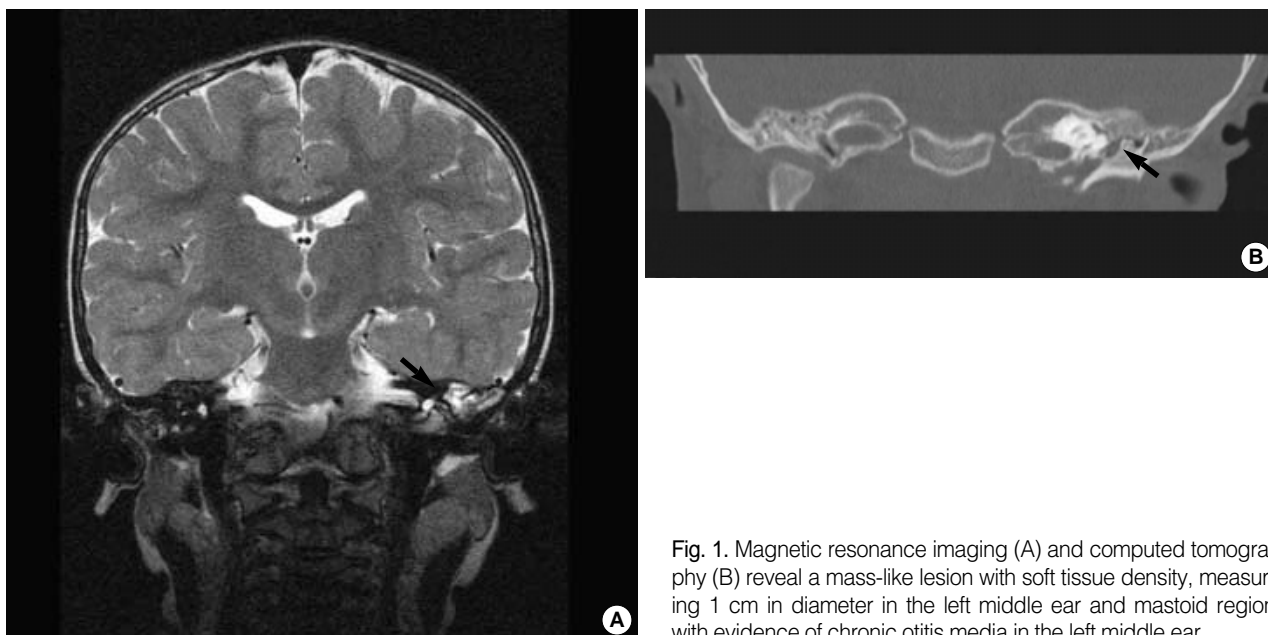


Fig. 1. Magnetic resonance imaging (A) and computed tomography (B) reveal a mass-like lesion with soft tissue density, measuring 1 cm in diameter in the left middle ear and mastoid region with evidence of chronic otitis media in the left middle ear.

## DISCUSSION

Heterotopic glial tissue was initially described in 1907 by Wolbach. Heterotopic glial tissues in various sites have since been reported, and these have been classified based on their locations and possible pathogenetic mechanisms.<sup>3</sup> Most of them were intracranial, leptomeningeal or extracranial midline lesions, and they were considered to represent displaced brain tissue during development. There have been only rare reports of extracranial non-midline lesions, and they have been found in the scalp, eye, orbit, lung, peritoneum, and middle ear.<sup>3</sup> The most common type of choristoma of the middle ear is a salivary gland choristoma and this is commonly associated with branchial cleft and facial nerve abnormalities, which suggests that choristomas arise as the products of developmental errors.<sup>1</sup>

Glial choristoma is rarely found in the middle ear cavity, and two terms, heterotopia and encephalocele (encephalic herniation), are often confused. However, they are different and have to be differentially diagnosed because the patients with encephalocele have the potential risk for meningitis.<sup>4</sup> The distinction is whether or not there is a patent connection with the cranial cavity, but it is sometimes difficult or even impossible to definitively determine whether a case is heterotopia or encephalocele. Pathogenetically, the commonly accepted theory is that heterotopic neural tissue is a variant of encephalocele. Most of the previously reported cases in the middle ear and mastoid lesion have been described as having an association with previous trauma, surgery, or an inflammatory process. Patients with this condi-

tion are older than the patients with their midline counterparts, and bony skull defects with CSF leakage are revealed by the radiological and operative finding in many cases, which supports the idea that lesions originate from an acquired encephalocele. In the literature, chronic infection or inflammation, previous trauma, or surgical procedures have been described as the predisposing factors for the development of middle ear heterotopia or encephalocele.<sup>2</sup> For our case, the 2-year-old boy had no previous history of trauma or surgical procedures, and there was no evidence of any connection with the central nervous system on the radiological study and there was no CSF leakage on the operation. Although the patient presented with otalgia and otorrhea, there were few inflammatory cells in the glial and surrounding connective tissue, as seen on the histological study.

Gyure *et al.*<sup>2</sup> reported 15 cases of neuroglial heterotopia of the middle ear and mastoid region, and they found that eight of ten patients for whom clinical information was available had a history of chronic infection, previous surgery, trauma or surgical evidence of a central nervous system (CNS) connection. The authors concluded that most of neuroglial choristomas were acquired encephaloceles rather than developmental lesions. However, in their cases, a few patients had no predisposing factors and no evidence of a connection of their lesions to the central nervous system. Lee *et al.*<sup>5</sup> also reported on a case having neither apparent predisposing factors nor evidence of a connection between the lesion and the central nervous system, and these case should be regarded as true neuroglial heterotopia rather than acquired encephalocele.

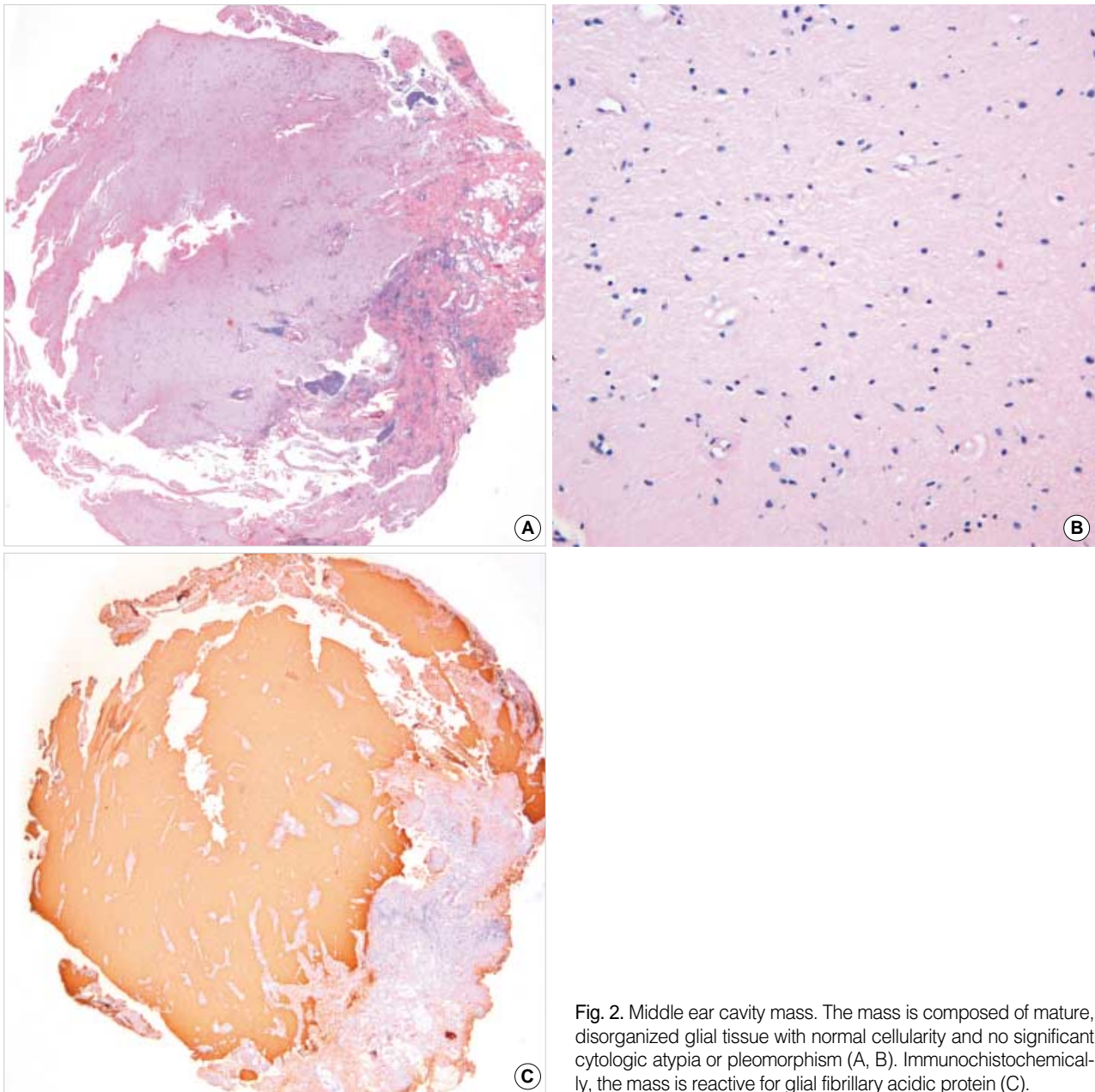


Fig. 2. Middle ear cavity mass. The mass is composed of mature, disorganized glial tissue with normal cellularity and no significant cytologic atypia or pleomorphism (A, B). Immunohistochemically, the mass is reactive for glial fibrillary acidic protein (C).

Histologically, heterotopic brain tissue is characterized by various proportions of neurons and glia with associated chronic inflammation, choroid plexus and ependymal or leptomenigeal components.<sup>5</sup> Iurato *et al.*<sup>6</sup> found that for idiopathic, true neuroglial heterotopia, there are no chronic inflammatory cells such as macrophages and lymphocytes, which differs from secondary encephalocele. Heterotopic glial tissue must be distinguished from true neoplasms such as glioma or ganglioglioma. In our case, the mass shows mature, normal glial tissue with few chronic inflammatory cells. There was no hypercellularity, nuclear atypism, or cellular pleomorphism, and true neoplasms were

easily excluded.

In summary, most of the previously reported cases of glial heterotopia of the middle ear can be regarded as acquired encephalocele associated with previous trauma, surgery, or inflammatory processes. However, our case was a 2-year-old boy without any history of congenital anomalies, trauma or surgery, and there was no evidence of a cranial bone defect or CSF leakage on the radiological and operative findings. Although the patient presented with otalgia and otorrhea, we believe that this case was a primary glial heterotopia rather than an acquired encephalocele.

## REFERENCES

1. Buckmiller LM, Brodie HA, Doyle KJ, Nemzek W. Choristoma of the middle ear: A component of a new syndrome? *Otol Neurotol* 2001; 22: 363-8.
2. Gyure KA, Thompson LD, Morrison AL. A clinicopathological study of 15 patients with neuroglial heterotopias and encephaloceles of the middle ear and mastoid region. *Laryngoscope* 2002; 110: 1731-5.
3. Park JH, Park YK, Kim KS, Kim BS. A case of conductive hearing loss by heterotopic neuroglial tissue. *Korean J Otolaryngol* 2003; 46: 696-8.
4. Dennis K, Heffner. Brain in the middle ear or nasal cavity: Heterotopia or encephalocele? *Ann Diag Pathol* 2004; 8: 252-7.
5. Lee JL, Kim KK, Park YK. Glial choristoma in the middle ear and mastoid bone: a case report. *J Korean Med Sci* 2004; 19: 155-8.
6. Iurato S, Bux G, Colucci S, *et al.* Pathology of idiopathic encephaloceles into the middle ear. *ORL J Otorhinolaryngol Relat Spec* 2002; 64: 73-9.